



PATHOLOGICAL EFFECTS OF CHROMIUM TRIVALENT SUPPLEMENTATION IN DIETS OF MALE RABBITS EXPOSED TO HEAT STRESS

M.J. Al-Saadi¹ and Bushra I. Al-kaisei²

¹Department of Veterinary Public Health, College of Veterinary Medicine, University of Baghdad, Iraq

²Department of Pathology, College of Veterinary Medicine University of Baghdad, Iraq

E-mail: mjd.j@covm.uobaghdad.edu.iq

Abstract

Current study was conducted to estimate the pathological effects of the chromium picolinate supplementation in diet of male rabbits, which were, exposed to heat stress on some organs, like, liver, small intestine, heart and testis, twenty four male rabbit were randomly divided into three groups, eight for each, first group were kept as a negative control group, put in normal suitable climate condition, supplied with basal diet without additional Chromium, while The other two groups were exposed to heat stress, their basal diet was consisted by; 0, 500 ppb of Chromium picolinate daily per each animals, respectively. All rabbit received feed and water *ad libitum*, the results revealed that heat stress groups showed clinical symptoms such as increased in breath rates, tachycardia, increased in water consumption and loss of appetite, meanwhile the 500 ppb chromium receiving group revealed toxic symptoms started by depression, lacrimation, diarrhea, and muscular tremors accompanied by some histological changes varied from fatty change, center lobular necrosis with pyknotic of nuclei in the liver cells, while there were congestion of blood vessels of mucosaa eosinophilic cells infiltrations in small intestine cells, also there were necrotic heart myofiber, vacuolating of heart muscle cells with increasing in interstitial with mononeucler cells infiltration in mayocardial cells. The testis tissues recorded a hypoatrophy of seminiferous tubules accompined with increasing in interstitial space. Based on results obtained in this study we found that chromium piclonate supplementation in diet of male rabbits had initiated some toxic effects and tissue damage in addition as a synergistic effects accompanied with the heat stress.

Keywords: Deppretron, hyperatrophy, vacuolation, fatty change

Introduction

Heat stress has classified into two types of effects, acute and chronic, depends up on the period of exposure and degree of ambient temperatures, the tissue damage which caused, including: pyknosis, apoptosis, some necrotic areas and an increase in center of melano-macrophage in liver tissues due to DNA digestion and cell membrane destruction (Barry *et al.*, 1999; Ellen *et al.*, 1989), some investigators observed that there were vacuolated in hepatic cells, degeneration with dilation and congestion of sinusoid, widespread necrosis, and infiltration of leukocyte in some parts of the liver and kidney in rabbits those exposed to hyperthermia (Hernandez *et al.*, 2018; Michael *et al.*, 2005). Several management and nutritional methods tried to reduce heat stress in which chromium supplements is one of the most important nutritional way that can be used to eliminate heat stress damage. Chromium is biologically highly active as portion of an oligopeptid (chromodulin) potentiating that has an ability to effect of insulin by enabling insulin bind to receptors at the cell surface. chromium piclonate is very important in carbohydrate, lipid and protein metabolism. Dietary trivalent chromium has very important nutrient role for human as well as in animals and used in higher dosages to offset a problems of malabsorption or to treat or pharmacological influence the chemistry of blood sugar control in diabetics and has previous researches on the basis of non-randomized clinical trails. chromium is one of essential trace elements that has an important for proper physiological function of lipid and carbohydrate metabolism (Journal of Medicinal Plants Research, 2011; Barry *et al.*, 1999). Absorbed Chromium is excreted primarily in urine tracts, by glomerular filtration, a small quantity is excreted via perspiration and bile juice. The needing for Chromium has been rising as a result of factors ordinarily referred to as

hyperthermia condition, particularly through different types of nutritional, metabolic stress, Liver is regarded the first organ metabolic and biotransformation of organic toxification (Madeeha, *et al.*, 2011). Chromium have sever effects by enter to hepatocytes resulting in reactive oxygen species (Ros) with tissues damages and apoptosis (Kikusato *et al.*, 2013; Frank *et al.*, 2000). Characterized by sinusoids, dilatation of hepatocytes (Anderson, 1997; Jamal *et al.*, 1991), the main objective of this study to investigated the pathological alteration in some of Rabbit tissue organs due to chromium piclonate supplementation into the diets of male rabbits exposed to heat stress.

Materials and Methods

Present study was carried out, in animal house of College of Veterinary Medicine, Baghdad University for 70 days started from 15 November 2018 - 30 January 2019, including 15 days for adaptation periods, Twenty four Healthy growing male rabbits of local strain, 2-3 months of age and weighing 1.200-1.400 kg, Each rabbit was housed in a standard hutch supplied with a basal diet and water. The whole hutch method was of the three-tier model, housed in well climate condition, cement floored pens, raised 130 cm up the ground. Each animal was dewormed and an acaricide bath was gave. The animals were divided randomly into three groups, eight animals with two replicate four to each, the first group put in normal climate conditions of 18 - 22 °C and humidity between 60 - 70% (28), and fed optimize based diet free from Chromium piclonate, according (Lindemann *et al.*, 2004) and kept as negative control group, while the two other two groups were subjected to severe heat stress (29.72 ± 0.3 °C; HT) (Pei *et al.*, 2011; Li *et al.*, 2012) and their Basale diet were consisted of 0, 500 ppb of Chromium piclonate respectively. All rabbits for all groups received feed and water *ad libitum*, at the end of study three animals from all

groups were sacrificed then visceral organs were removed from carcasses and a specimens of (1) cubic centimeter in diameter pieces of, liver, small intestine heart and testis, were taken, cleaned from adipose and connective tissues, then excised and fixed in (10%) formaldehyde, the histological specimens were dehydrate in the serial graduate of ethyl alcohol concentrations (50%, 70%, 80%, 90%, 100%), after that clearing in xylol, and embedded in paraffin, the blocks of histological specimens were sectioned at six micrometers by using rotatory microtome, the histological sections were stained by hematoxylin and eosin for histological examination (Aengwanich *et al.*, 2004).

Results and Discussion

In current study, the second or (positive group) that exposed to heat stress but, no chromium piclonate supplemented received in their diet, showed some clinical symptoms, characterized by acceleration in breath rates, tachycardia (increase in heartbeat), lacrimation, increased in water consumption and loss of appetite, while the third group or, the 500 ppb chromium piclonate receiving group revealed some clinical symptoms that refer or indicate to toxic signs, which started by depression, followed by, varied signs, from, lacrimation, diarrhea, and muscular tremors which contentious up to end of experiment, These results is full agreement with (Zhang *et al.*, 2003) who studied the exposure to high level dose of chromium. On the other hand, the first group or (negative control group) is still within normal health status due its normal climate condition and supplied with normal basal diet free from any feed additives.

Gross Lesions

There is no important lesions were recorded in control negative group in grossly and microscopical examination, while the livers of the 500 ppb group showed paleness in color, enlargement, rounded edges and surfaces petechial hemorrhages in some areas, (Figure 1), same alteration were seen in testis characterized by swollen and enlargement in parenchymal tissues accompanied with congestion in surfaces blood vessels (Figure 2) in intestines there is congestion and petechial hemorrhage has been showed in (Figure 3), while there were not clear gross lesion appeared on heart organs for both groups exposed to heat tress including 500 ppb receiving group.

Microscopic Examination

Microscopic examination of the livers of control negative group were normal arrangement of the hepatocytes in cords around the central lobular vein and normal sinusoids while the liver of the groups that exposed to hyperthermia and untreated with chromium revealed fatty change, ballooning hydropic dehydration, center lobular necrosis, these degenerative effects was may be attributed to the activation of mitochondrial reactive oxygen species (ROS) (Bancroft and Stevens, 1982), that might be lead to cytotoxicity, apoptotic cell death, and necrosis; but lesions in the 500 ppb chromium receiving or third group that exposed to hyperthermia, the livers declared congestion of central veins with dilated sinusoids, many hepatocytes underwent fatty change with cellular necrosis markedly around terminal hepatic vein with center lobular necrosis characterized by pyknotic nuclei (Figure 4), these toxic changes, is closely agree with (Farag *et al.*, 2006) who reported that trivalent chromium piclonate form a compounds with intracellular

macromolecules counting genetic material, finally accountable for the toxic and mutagenic capacities of chromium (Dubois and Belleville, 1991). Same trend was observe by (Li *et al.*, 2011) in his study who found, that chromium forming biochemical complexes are not biodegradable and accumulate to yielded indirect and direct toxic alterations to living cells (Antonini *et al.*, 2003), furthermore ,and additional to the effects of chromium, (Pitts, 2018) who was suggest in a research that the congestion of the central lobular regions of liver was might be attributed to the overloaded of mitochondria of liver cells during stress which caused increased in blood supply as compensatory mechanism.

On the other hand, the microscopic examination of intestine of third group receiving 500 chromium piclonate in diets, also showed varied lesions started from catarrhal inflammation characterized by increased in number and size of goblet cells with increase in mucin secretion, many enterocytes sloughing and desquamates appeared on some areas, as an appear in (Figure 5) in other section observed that, most mucosa and submucosa showed congestion blood vessels and eosinophils inflammation (figure 6.), despite Chromium (III) has low oral toxicity because it is insoluble in water and weakly absorbed, (Frank and Danielsson, 2000). Based on the obtained results in this study, its our opinion that the high doses and long period of acting of chromium accompanied by the effects of heat stress might be play an active role for increased free radicals levels result to histological degeneration as a synergetic effects in animals for long exposed to heat stress and high dose of chromium trivalent.

In such trend the heart tissue of 500 ppb chromium receiving (third group) showed fragmentation and vaculation of myofibers with necrosis of myocardial cells in addition to present an areas of congestion and hemorrhages in heart muscles tissues, (Figure. 7) furthermore , in other sections showed that there were enlargement of heart cells, swollen myocardial cells with reduced nuclei and cloudy enlarged myocardial cells with acute granular degeneration, heat stress, pathological lesions, characterized by disordered arrangement of cells and loss of striations, along with karyopyknosis and loss of nuclear definition these results are in a good agreement with (Pitts, 2018).

On the other hand, the histopathological changes in the testicular tissue of male rabbits of 500 ppb chromium receiving and as shown in (Figure 8), characterized by, shrinkage of seminiferous tubules with marked widening of interstitial spaces while in other sections shown necrosis of almost the spermatogenic cells, and disappearance of sperms, such histological alteration might be due to synergistic effects of hyperthermia and long term exposure to chromium piclonate despite its low toxicity, these results is agree with (Michael *et al.*, 2005; Farag *et al.*, 2006) whom suggest that chronic exposure to chromium increased concentration of free radicals H_2O_2 , OH^- and GSH, accompanied with low levels of the antioxidant vitamins A, C and E, forming oxidative stress in the different tissue cells of testis due to decrease in levels compound that scavenging of free radicals levels, such trend suggested that these results might be indicate e to synergistic effects of hyperthermia accompanied with the toxic effects of chromium piclonat. (Frank and Danielsson, 2000); Cohen *et al.*, 1993). However, It worthy to mention that, despite the validity of these results it has

been questioned due to insufficient reporting in such direction, furthermore, in contrast to our results in present study there were multiple studies and many investigators, found that chromium piclonate have protective role against deleterious effects of heat stress (Alsaied *et al.*, 2008; Chang, and Mowat, 1992; Dalolio, *et al.*, 2018).

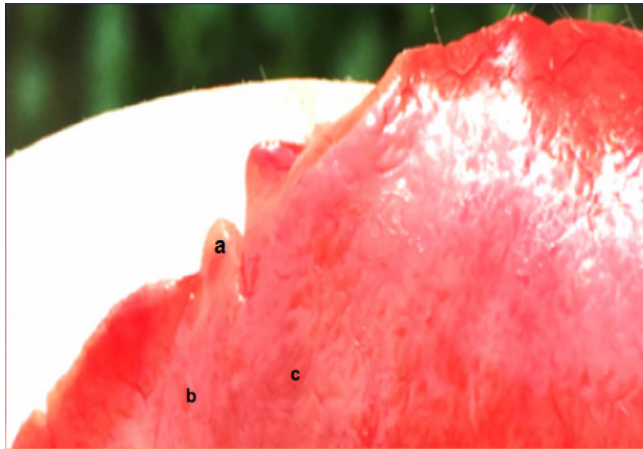


Figure1: gross lesion of liver of third group (500 ppb receiving in diets) showed (a) irregular enlargement, rounded edges (b) whitish spotted areas (c) surfaces petechial

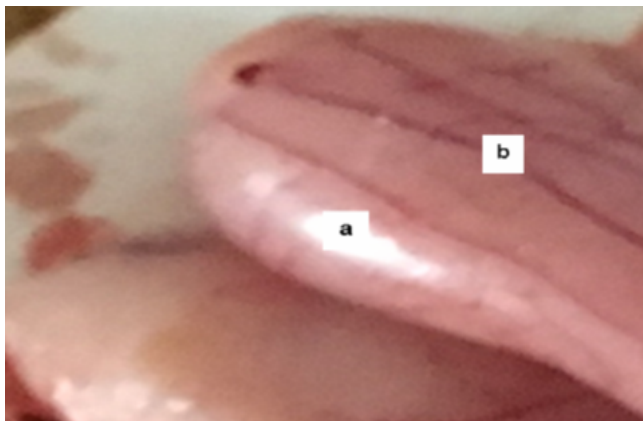


Figure 2 . gross lesion of testis of 500 ppb of chromium supplemented group Showed(a) enlargement of tissue organ with (b) congestion of surface blood vessels

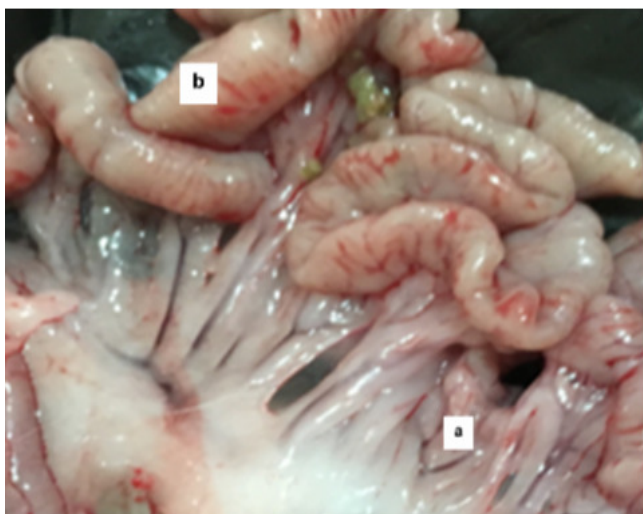


Figure 3. gross lesion of intestine of second group showed (a) marked congested blood vessels with (b) petechial hemorrhage in surface layer

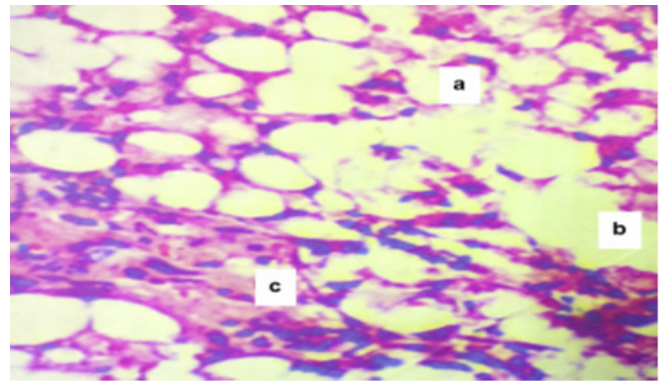


Figure 4 : liver of third group (500ppb chromium receiving in diets) (a) fatty change (b) Ballooning hydropic dehydration (c) center lobular necrosis with pycnotic nuclei x40 H&E stain

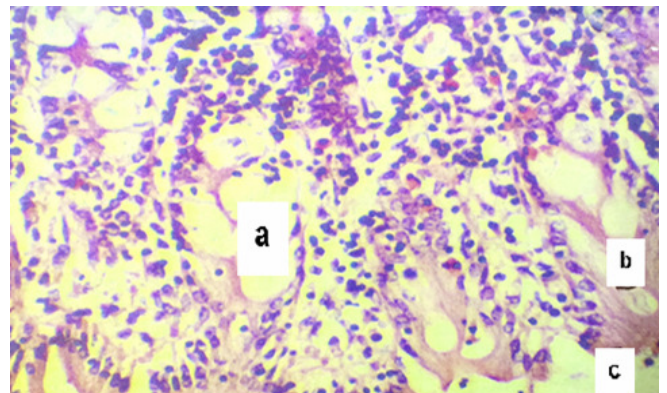


Figure 5: intestine of third group (hyper thermic an 500 ppb chromium receiving group) showed (a) increased in size and number of goblet cells (b) increase mucine secretions (c) sloughing and desquamations of mucosa x40 H&E stain

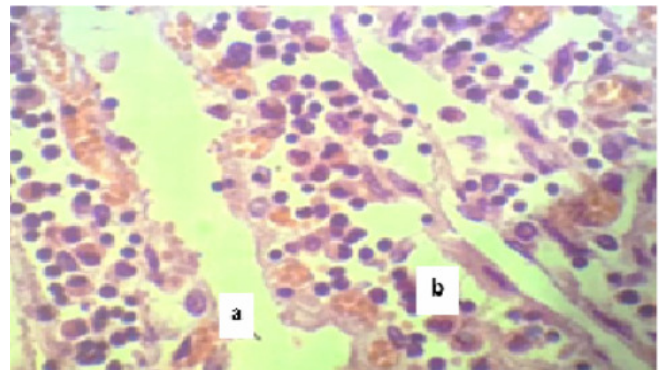


Figure 6 . : intestine of third group (500 ppb chromium piclonat) showed (a) congestion of blood vessels of mucosaa (b) eosinophilic cells infiltrations x40 H&E stain

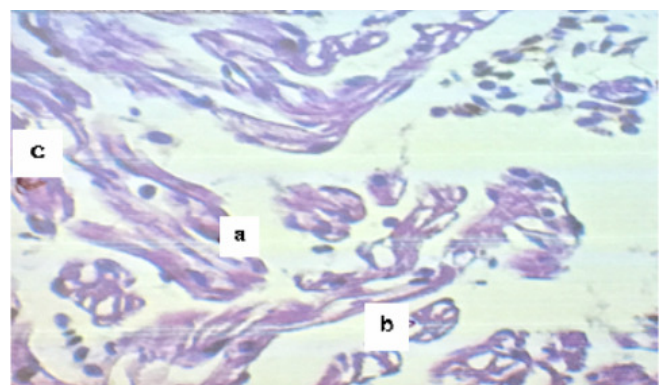


Figure 7.: heart of 500 ppb of chromium supplemented group Showed (a) necrotic heart myofibril (b) vacuolating of heart muscle with (c) increasing in interstitial with mononuclear cells infiltration space x40 H&E stain

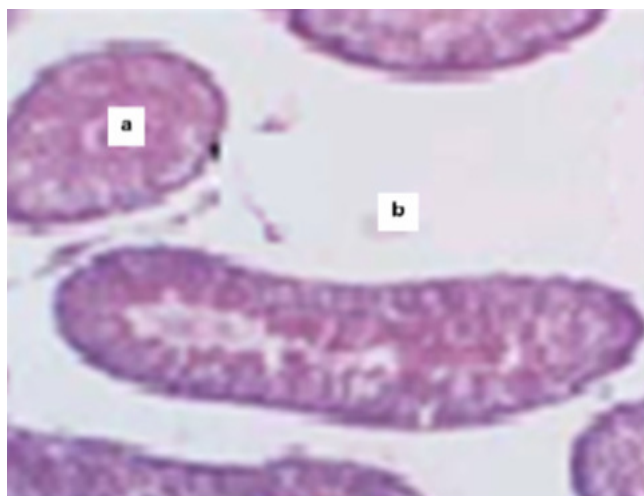


Figure 8: testis of 500 ppb of chromium supplemented group Showed (a)hypotrophy of seminiferous tubules accompanied with(b) increasing in interstitial space (H&E; X 40)

References

- Aengwanich, W. and Simaraks, S. (2004). Pathology of heart, lung, liver and kidney in broilers under chronic heat stress. *Pathology*; 26(3): 418.
- Alsaied, A.H.; Mona, N.S.; Hamdy, A.B. and Michael, I. (2018): Effect of Environmental Climatic Conditions on levels of Some Hormones, Vitamins and Trace Elements in Blood and Seminal Plasma of Rabbits *International Journal of Biotechnology and Recent Advances*, 1(1): 18-23.
- Anderson, R.A. (1991). Chromium as an essential nutrient for humans. *Regulatory Toxicology and Pharmacology*, 26: S35-S41.
- Antonini, J.; Lewis, A.; Roberts, J. and Whaley, D. (2003). Pulmonary effects of welding fumes: review of worker and experimental animal studies. *AM. J. Ind. Med.*; 43: 350-360.
- Bancroft, J. and Stevens, A. (1982). *Theory and practice of histological techniques*. 2nd edition. Churchill Living stone, 647.
- Barry, M.A.; Behnke, C.A. and Eastman, A. (1990). Activation of programmed cell death (apoptosis) by cisplatin, other anticancer drugs, toxins and hyperthermia. *Biochemical pharmacology*, 40(10): 2353-62.
- Chang, X. and Mowat, D.N. (1992): Supplemental chromium for stressed and growing feeder calves. *Journal of Animal Science*, 70: 559-565.
- Cohen, M.D.; Kargacin, B.; Klein, C.B. and Costa, M. (1993). Mechanisms of chromium carcinogenicity and toxicity. *Crit. Rev. Toxicol.* 23(3): 255-281.
- Dalolio, F.S.; Albino, L.F.T.; Silva, J.N.; Campos, P.H.R.F.; Lima, H.J.D.; Moreira, J. and Junior, V.R. (2018). Dietary chromium supplementation for heatstressed broilers. *World's Poultry Science Journal*, 74(1): 101-116
- Dubois, F. and Belleville, F. (1991). Chromium – physiological role and implications for human disease. *Pathologie-Biologie (Paris)*, 39: 801-808.1
- Ellen, G.; Vanloon, J.W. and Tolsma, K. (1989). Cooper, chromium, manganese, nickel and zinc in kidneys of cattle, pigs and sheep and in chicken livers in the Netherlands. *Zeitschrift für Lebensmittel-Untersuchung und -Forschung*, 189: 534-537.
- Farag, A.M.; May, T.; Marty, G.D.; Easton, M.; Harper, D.D.; Little, E.E. and Cleveland, L. (2006). The effect of chronic chromium exposure on the health of Chinook salmon (*Oncorhynchus tshawytscha*). *Aquatic Toxicology*, 76: 246-257.
- Fekete, S. and Gippert, T. (1986). Digestibility and Nutritive Value of Nineteen Important Feedstuff For Rabbits. *J. Appl. Rabbit Res.*, 9: 103-108.
- Frank, A.; Anke, M. and Danielsson, R. (2000). Experimental copper and chromium deficiency and additional molybdenum supplementation in goats. I. Feed consumption and weight development. *Science of the Total Environment*, 249: 133-142.
- Hernandez-Lopez, J.R. *et al.* (2018). Thermal Effect of Acute and Chronic Stress on Hepatic and Renal Tissue of the Pacific Sardine, *Sardinops sagax caeruleus* (Jenyns, 1842): *International Journal of Morphology*; 36(1): 212-221.
- International Programme on Chemical Safety (IPCS) (2006). Inorganic chromium (III) compounds. Draft. Concise International Chemical Assessment Document. WHO. Geneva.
- Jamal, Z.M.; Vjekosla, V.S.; Jelena, P.G. and Emil, S. (1991). Distribution of chromium in the internal organs of potassium chromate treated chicks. *Veterinary and Human Toxicology*, 33: 223-225.
- Journal of Medicinal Plants Research* (1996). Vol. 5(16), pp. 3940-3945, 18 August, 2011 Available online at <http://www.academicjournals.org/JMPR> ISSN -0875 ©2011 Academic Journals Full Length Research Paper.
- Kikusato, M. and Toyomizu, M. (2013). Heat stress induced overproduction of mitochondrial reactive oxygen species is down-regulated in laying-type chickens, in Energy and protein metabolism and nutrition in sustainable animal production.; Springer 267-268.
- Li, Z.H.; Li, P. and Randak, T. (2011). Evaluating the toxicity of environmental concentrations of waterborne chromium (VI) to a model teleost, *oncorhynchus mykiss*: a comparative study of *in vivo* and *in vitro*. *Comparative Biochemistry and Physiology Part C* 153: 402-407.
- Lindemann, M.D.; Carter, S.D.; Chiba, L.I.; Dove, C.R.; LeMieux, F.M. and Southern, L.L. (2004). A regional evaluation of chromium tripicolinate supplementation odiets fed to reproducing sows. *Journal of Animal Science*, 82: 2972-2077.
- Madeeha, M.; Shahzad, H.; Farnaz, M.; Tipu, S.; Hussain, A.; Abdul, H.; Naila, A. and Khan, U. (1997). The effect of supplemental dietary chromium on blood glucose, body weight and liver enzymes of rabbits.
- Michael, M.; Aruldas, S.; Subramanian, P.S.; Vengatesh, G.; Gowri, C.; Govindarajulu, P. and Akbarsha, M.A. (2005) : Chronic chromium exposure-induced changes in testicular histoarchitecture are associated with oxidative stress: study in a non-human primate (*Macaca radiata* Geoffroy) *Human Reproduction, Advance Access publication*, 20(10): 2801-2813.
- Pei, Y.; Wu, Y. and Qin, Y. (2012). Effects of chronic heat stress on the expressions of heat shock proteins 60, 70, 90, A2, and HSC70 in the rabbit testis. *Cell Stress and Chaperones*; 17(1): 81.

- Pitts, J. (2018). What Causes a Congested Liver? Health guidance for better health, *International Journal of Morphology*, 36(1): 212–21.
- Shu, Tang, Yingjun Lv Hongbo, Chen, Endong Bao (2014). Comparative Analysis of α B-Crystallin Expression in Heat-Stressed Myocardial Cells In Vivo and In Vitro January : 2014 PLoS ONE 9(1):e86937
- Zhang, H.J. (2003). Heat-induced liver injury in old rats is associated with exaggerated oxidative stress and altered transcription factor activation. *The FASEB journal*; 17(15): 2293-5.