



POTENTIAL EFFECTS OF GLIMEPIRIDE AND A HERBAL MIXTURE ON HYPERGLYCAEMIA, HYPERCHOLESTEROLAEMIA AND OXIDATIVE STRESS

Bassant M.M. Ibrahim^a, Abeer A.A. Salama^a, Nemat A. Yassin^a, Sawsan S. Mahmoud^a,
Amina A. Gamal El-Din^b, Nermeen A. Shaffie^b and Doha H. Abou Baker^{c, ✉}

^aPharmacology Department, Medical Research Division, National Research Centre, Dokki, Giza, Egypt, Po:12622.

^bPathology Department, Medical Research Division, National Research Centre, Dokki, Giza, Egypt, Po:12622.

^cMedicinal and Aromatic Plants Department, National Research Centre, Dokki, Giza, Egypt, Po:12622.

✉Corresponding author: dohaboubaker@gmail.com

Abstract

Diabetes mellitus (DM) is a common chronic depleting disease usually associated with other disorders as hyperlipidaemia. The present study aims at studying the effect of glimepiride and aqueous extract mixture formed of *Hibiscus sabdariff* (roselle), *Origanum majorana* (marjoram), *Matricaria chamomilla* L (chamomile) and *Hyphaene thebaica* (doum) as hypoglycaemic, hypocholesterolaemic and antioxidant agents in streptozotocin-induced diabetic rats. Animals were classified into: Normal group, positive control group: Streptozotocin intraperitoneally (untreated hyperglycaemic) for 48 hours, treated groups orally for 2 successive weeks: Glimepiride (0.1 mg/kg) and mixture groups (250, 500 mg/kg). Blood glucose, alpha amylase, total cholesterol levels and total antioxidant capacity were measured in sera. Histopathologic examination was done for pancreatic tissue. Streptozotocin elevated blood glucose, alpha amylase and total cholesterol levels, and reduced HDL levels and total antioxidant capacity. Histopathologic examination showed that it caused damage of pancreatic tissue, while glimepiride and the mixture in dose dependent manner; reduced blood glucose, alpha amylase and total cholesterol levels and increased HDL cholesterol levels and total antioxidant capacity, they also improved the damaged pancreatic tissue. Glimepiride and the mixture had hypoglycaemic, hypocholesterolaemic and antioxidant effects in cases of mild pancreatic damage. The effect of the mixture was dose dependent as high dose showed more improvement in all biochemical parameters and better pancreatic histopathologic picture. Glimepiride effect was the best regarding all investigations except for its effect on HDL it was the least.

Keywords: Antioxidant; Hyperglycaemia; Hypercholesterolaemia; Roselle; Marjoram; Chamomile; Doum.

Introduction

Diabetes Mellitus (DM) affects hundreds of millions of the world population; it is expected to exceed 693 million by 2045 (Cho *et al.*, 2018). In DM, affection of β -cells of the affects blood glucose metabolism, that in turn induces elevation of blood glucose level. DM is characterized by a group of metabolic disorders that take place due to chronic hyperglycaemia associated with disturbance in fat, protein and carbohydrate metabolisms, either due to abnormal insulin secretion or action (Ortega *et al.*, 2017), so it is common to be associated with hyperlipidaemia (Jung and Choi, 2014). Hindering digestion and absorption of carbohydrates in small intestine are the best paramount means for diabetes therapy, this can be reached by inhibition of alpha amylase (Salama *et al.*, 2017). Also protection of beta cells of pancreas against damage or aiding their regeneration by the use of chemicals that have antioxidant abilities plays an important role in management of hyperglycaemia and other complications of diabetes (Kamalakkannan and Prince, 2006). This can be based on the fact that glucose auto-oxidation in hyperglycaemia as well as over activation of polyol pathway together with protein glycation compromise the great burden of oxidative stress in cases of hyperglycaemia (Hamilton *et al.*, 2003).

Glimepiride, an anti-diabetic sulfonylurea with antioxidant abilities, it acts rapidly and its effect persists longer than other sulfonylureas, moreover it is given in low dose, all of these give it privilege over other sulfonylureas (Mohamed *et al.*, 2012).

Many natural herbs can be used as supplements for controlling high blood glucose level and hyperlipidaemia by

adopting different mechanisms of action one of which is their antioxidant effects. Natural herbs are being now put into consideration for use as supplements in managing health disorders, due to their low toxicity and sufficient efficacy, in addition to their low costs when compared to standard medications.

In Egypt roselle, which is an annual dicotyledonous herbaceous shrub, is used in traditional medicine for treatment of different diseases including elevated blood pressure, elevated body temperature, hepatic disorders and it has been also reported that it had hypoglycaemic effect (Salam *et al.*, 2016).

Another herb is marjoram which is an aromatic herb that is a member of Lamiaceae family and its origin was in Egypt. Marjoram has strong antioxidant potential (Ulewicz-Magulska and Wesolowski 2019).

Also chamomile which is a member of Asteraceae family, is a very old medicinal plant, that is still and will continue to be used as a medicinal remedy due to its content of bioactive phytochemicals. Its dried flowers contain mono, sesquiterpenoids and flavonoids that contribute to its medicinal characteristics through their antioxidant activities (Al-Dabbagh *et al.*, 2019).

In addition to the above mentioned herbs, Doum that is an Egyptian desert palm tree native to the Nile valley, is used as medicinal plant. It possesses anti-diabetic and antihypertensive effects (Aremu and Fadele, 2011).

Considerable population all over the world consume medicinal plants, that can be investigated for their potential effects as supplements for controlling diabetes. That's why,

the present study is conducted to elucidate the effect of a mixture aqueous extract formed of roselle, marjoram, chamomile and doum as antidiabetic, hypocholesterolaemic and antioxidant agent in STZ-induced diabetes in adult male albino rats.

Materials and Methods

Materials

Plants:

Half kilo of the following plants, the red calyces of roselle, all herb of marjoram, flowers of chamomile and the outer part of doum fruits were extracted with cold water over night then filtered and re-extracted by cold water till exhaustion. All filtrates of each plant were combined, evaporated under reduced pressure and then lyophilized.

A mixture aqueous extract contains equal weights of each extract was prepared, for animal treatments.

Animals:

Male Wistar Albino rats, weighing ranged from 150-175gm were used for acute toxicity study and efficacy study. Males were used to avoid the effect of female hormones on blood glucose, total cholesterol and HDL levels, as it is an endocrinology based study that tests the effects of herbs on diabetes and hypercholesterolaemia which is an associated metabolic disorder.

The animals were obtained from the animal house colony of the National research centre, Dokki, Giza, Egypt. The animals were housed in standard metal cages in an air conditioned room at $22 \pm 3^\circ\text{C}$, $55 \pm 5\%$ humidity and provided with standard laboratory diet and water ad libitum. All experimental procedures were conducted in accordance with the guide for care and use of laboratory animals and in accordance with the Ethics Committee of the National Research Centre: All animals received humane care according to the criteria outlined in the "Guide for the Care and Use of Laboratory Animals" prepared by the National Academy of Sciences and published by the National Institutes of Health (NIH publication 86-23 revised 1985), "No pain, suffering, distress or lasting harm by the successful use of anaesthesia to animals. Experiment ended when no further observations were to be made for it, by following humane methods for animal sacrifice" (NIH 1978).

Chemicals and Drugs:

- STZ, diethyl-ether, sodium citrate, citric acid and formaldehyde were purchased from Sigma Aldrich Chemical Co., USA, sterile saline was purchased from ADWIC Egypt.
- Glimpiride was purchased from Sanofi-Aventis, Egypt

Diagnostic kits:

- Kits for determination of blood glucose, total antioxidant and alpha amylase levels in rat serum were purchased from Biodiagnostic company, Egypt.

Apparatus:

Spectrophotometer. Olympus CX41 research microscope, CCD digital camera Olympus DP-12 attached to the Olympus CX41 research microscope.

Methods

Pharmacological Study:

Acute Toxicity study:

Ten rats were classified equally into negative control that received 1 ml saline orally (po), and treated group received 1 ml of the mixture aqueous extract, which was prepared by dissolving 5g/kg in distilled water. The rats were observed over the following 24 hours for change in behaviour, bowel habits or death. Then the rats were observed over the following 15 days for changes in behaviour or weight or bowel habits. The mortality % during the first 24 hours was zero. Accordingly the efficacy study experimental doses used were 250 and 500 mg/kg.

Efficacy Study:

Study Design: Sixty animals used were enrolled in the study as follows:

- 1st group (8 rats): Normal rats were given 1ml tap water orally daily
- 2nd to 5th groups (52 rats), were diabetic groups that were induced by fasting the rats for 24 h and then intraperitoneally injecting them with a single dose of 45mg/kg body weight of freshly prepared streptozotocin (STZ) dissolved in citrate buffer pH 4.5 (Ramesh and Pugalendi 2006).

After 48 hours blood glucose level was measured for all rats. Rats with glucose levels >200 mg/dl (40 rats), were used in the experiment and divided equally into the following groups:

- 2nd group remained without treatment and was considered positive control diabetic rats.
- The 3rd group, was given glimepiride p.o in a dose of 0.1 mg/kg (Salama *et al.*, 2017), for two successive weeks.
- The 4th and 5th groups were given 250mg/kg and 500 mg/kg of aqueous extract of the mixture aqueous extract orally daily for two successive weeks.

Biochemical parameters: Twenty four hours after the last dose of treatment, blood was obtained from all groups of rats after being lightly anaesthetized with ether by puncturing retro-orbital plexus, the blood was allowed to flow into a clean dry centrifuge tube and left to stand 30 minutes before centrifugation to avoid hemolysis. Then blood samples were centrifuged for 15 minutes at 2500, rpm the clear supernatant serum was separated and collected by Pasteur pipette into a dry clean tube to use for determination of serum level of glucose, total antioxidant capacity and alpha amylase level in serum according to the methods described by Trinder 1969; Koracevic *et al.*, 2001; Bernfeld 1955.

Histopathologic study: At the end of the experiment; animals were sacrificed. Pancreas (splenic part), were dissected and extracted from sacrificed animals. Organ tissues were fixed in 10% buffered formalin, processed through ascending grades of alcohol, cleared in xylene and prepared into paraffin blocks. Serial sections 5 microns thick were prepared from each block and stained with haematoxylin and eosin for routine histopathologic study (Drury, 1976).

The sections were examined under an Olympus CX41 research microscope at the Pathology Department; National Research Centre. Slide tissue microphotography was done using CCD digital camera Olympus DP-12 attached to the Olympus CX41 research microscope. Digital photomicrographic sections were taken at various magnifications.

Statistical analysis

Comparison between means was carried out using one way analysis of variance (ANOVA), followed by Tukey Kramer's multiple comparison test. $p < 0.05$ was considered as being significant. Graph pad prism software (version 6) was used to carry out statistical tests.

Results

In the present study, the acute toxicity study revealed no deaths in all groups of animals within the first 24 hours after administration of a single dose of the mixture aqueous extract which was the maximum soluble dose (5gm/kg). When blood samples were collected 15 days after administration for complete blood picture, liver and kidney function examination, no abnormalities were detected, and the doses selected for the efficacy study were 250 mg/kg and 500 mg/kg.

Results of the efficacy study expressed in Table 1 showed that administration of a single dose of freshly prepared streptozotocin (STZ) (45mg/kg) intraperitoneally (IP), produced significant elevation in blood glucose level by 222.66% and significant increase of alpha amylase activity by 143.98% in serum of rats of positive control group after of two successive weeks without any treatment, when compared to normal animals.

On the other hand treatment with glimepiride group (0.1 mg/kg) po, caused a significant reduction in blood glucose level by 68.64% and significant reduction of alpha amylase activity by 61.73 % when compared to positive control group.

Also treatment with mixture aqueous extract (250 & 500 mg/kg) po, caused a significant reduction in blood glucose level by 23.14% & 26.32% respectively and significant reduction of alpha amylase activity by 7.51% & 10.02% respectively when compared to positive control group.

In the present study, the results of biochemical parameters tests investigating the hypoglycaemic effects of glimepiride and the mixture, and comparing them to the normal and positive control (STZ) groups; were confirmed by histopathologic examination of pancreatic tissues obtained from all groups.

Examination of pancreatic tissue excised from normal control rats showed that the islets of langerhan's were frequently distributed amidst pancreatic acini. All islets had well defined borders, large size and abundant cellularity. The cells were arranged in organized manner with preserved architecture. The surrounding pancreatic acini were lined by pyramidal cells and showed ample, apical cytoplasm and bland, basophilic, baso-luminal nuclei (Fig.1).

On the other hand pancreatic tissue excised from diabetic untreated rats (positive control), showed marked reduction in number and size of islets of langerhan's, which were fewer and shrunken, much smaller in size. Islets had ill-

defined borders, some being stellate in shape. In addition, Beta cells within the islets of langerhans; as demonstrated by anti-insulin monoclonal antibody; showed reduction in number, as well as signs of degeneration and necrosis. Vacuolar degeneration was observed within islet cells especially at the center. Hyaline bodies were seen. Inflammatory cells were observed at the periphery of scattered islets. The best improvement group orders, was noticed in the group treated with glimepiride, as this group showed improvement in islet size, number, cellularity and architecture with no signs of degeneration. On the other hand rats treated with Mixture low dose (250 mg/kg), didn't show any improvement as islets appeared shrunken, markedly hypocellular with necrosis within constituent cells; especially at the centre, while the Mixture high dose (500 mg/kg), showed mild improvement where islets still showed small size, hypocellularity and vacuolar degeneration; especially at the center (Fig.1).

The biochemical results of our study displaying the effect of treatment on total cholesterol and HDL levels in serum; were expressed in Table 2, and showed that STZ administered IP, produced significant elevation of total cholesterol level by 38.98 % and significant reduction of HDL by 47.8 %, when compared to normal animals after two weeks without receiving treatment.

But treatment with glimepiride (0.1mg/kg) and mixture aqueous extract (250 & 500 mg/kg) po for two successive weeks, caused a significant reduction in total cholesterol level by 11.8% , 6.25 % and 10.01% respectively and caused significant elevation of HDL by 72.47%, 83.56% and 170.55% respectively when compared to positive control group.

Results of total antioxidant capacity of glimepiride and the mixture aqueous extract used in our study were expressed in Table 3 which revealed that administration of STZ IP caused significant reduction of total antioxidant capacity by 32.15% when compared to normal group.

While treatment with glimepiride (0.1 mg/kg) po and the mixture aqueous extract in our study (250&500 mg/kg), elevated the total antioxidant capacity by 171.31%, 26% and 43.25% respectively when compared to positive control group.

Discussion

The results of the effect of administration of a single dose of STZ (45mg/kg) to rats IP on blood glucose level, alpha amylase activity, total cholesterol, HDL levels and antioxidant capacity, are in agreement with the results of Salama *et al.* (2017), who also revealed that STZ given IP to rats caused significant elevation of blood glucose level, alpha amylase activity caused hypercholesterolaemia together with reduction of HDL level in serum of experimental rats. The hyperglycaemic effect of STZ is due to its acute cytotoxic effect on β cells of pancreatic islets of Langerhans, which in turn impairs insulin secretion leading to hyperglycemia and consequently diabetes. Also Gundala *et al.* (2018), revealed that type 2 DM induced by STZ in Wistar rats is used to mimic a model of human type 2 DM where peripheral insulin resistance leads to hyperglycemia. Moreover, high blood glucose level was associated with reduced total antioxidant capacity in our study and was proven in previous studies as Mohamed *et al.* (2012), also revealed that STZ given in a

single dose of 50 mg/kg also increased blood glucose levels and oxidative stress biomarkers in rats.

In the present study, glimepiride showed marked hypoglycaemic effect in STZ hyperglycaemic rats which can be explained by what Mohamed *et al.* (2012), previously stated that it possessed insulin secreting stimulant effect, through binding to pancreatic beta cells receptors which in turn causes closure of potassium ATP channels followed by opening of calcium channels which finally leads to insulin release. Also the histopathologic picture of glimepiride in our study is in agreement with the findings of Mir *et al.* (2008), who revealed that treatment of diabetic rabbits with glimepiride increased the number of pancreatic beta cells and restored their morphology protective effect could be attributed to the antioxidant properties of glimepiride which was proven in the present study and is in accordance with the study of Mohamed *et al.* (2012), who revealed the antioxidant effect of glimepiride to its hypolycaemic effect and hence glucose autoxidation abolishing.

On the other hand, the results of the effect of treatment with the mixture aqueous extract when each was given alone in other studies were in agreement with the results of the present study as: Roselle was capable of lowering blood glucose level in diabetic rats induced by STZ in the study done by Mardiah *et al.* (2014). They associated the decreased levels of glucose with improvement in the number of β cells producing insulin in pancreatic cells. The effect of roselle may be due to the presence of anthocyanins, flavonols and protocatechoic acid as well as other phytochemicals which also contributed to its antioxidant activities. Moreover Kamel (2014) revealed that administration of marjoram oil reduced blood glucose values to near normal and explained that the mechanism of action of marjoram oil is similar to anti-diabetic glibenclamide action which is a sulfonylurea. Marjoram effect may be due to its rich contents of phenolic, flavonoids, and tannins together with phenolic glycosides (Salam *et al.*, 2016), that played an important role in the antioxidant effect of the mixture aqueous extract in our study. In addition to the glucose lowering effects and antioxidant activities of roselle and marjoram, also chamomile has glucose lowering effect and antioxidant activity due to its content of umbelliferone which was proven to significantly elevate the plasma insulin level in rats treated with chamomile when compared to untreated diabetic rat, so it led to reduction in the blood glucose level in the study of Ramesh and Pugalendi (2006), who also stated that it has high content of flavonoid in it: pigenin, luteolin, and quercetin, which comprise 16.8%, 1.9%, and 9.9%, respectively, of total flavonoids. Chamomile is also rich in polyphenolic compounds like coumarins which together with herniarin, umbelliferone, and esculetin constitute approximately 0.1% of the total constituents. Therefore chamomile is considered one of the richest sources of natural antioxidants such as flavonoids. It is noteworthy knowing that administration of flavonoids extracts to diabetic rats

increases adiponectin levels that enhance the hypoglycemic effect of insulin without changing insulin level in blood, which enforces the hypoglycaemic and antioxidant role played by Doum in our study as it is rich in flavonoids and saponins and tanins (Salam *et al.*, 2016).

The hypocholesterolaemic effect of the mixture aqueous extract and its ability to elevate the low HDL which were evident in the present study, were also previously reported in the study done by (Salam *et al.*, 2016), whose results were consistent with ours as they had proven the hypocholesterolaemic effect of the mixture aqueous extract, but in their study the mixture aqueous extract didn't elevate the level of HDL in serum of rats. They revealed the hypolipidaemic effect of the mixture aqueous extract to its high content of phytochemical constituents such as phenolics, flavonoids, tannins and saponins. Saponins were reported to inhibit pancreatic lipase activity in mice fed with high-fat diet, they increased fat excretion as a result of reduction of absorption of dietary fats in the intestine. Also, tannins had been known for their capability of inhibition of lipid absorption.

The antioxidant activity of the mixture is due to the high content of natural antioxidants in each single constituent of the mixture as phenolics, flavonoids. The antioxidant capacities of these constituents in herbs was proven in previous studies to contribute to their efficacy in experimental pharmacological studies (El-Gengaihi *et al.*, 2016a,b; 2020; Ibrahim *et al.*, 2016; Mossa *et al.*, 2015; Mostafa *et al.*, 2016; Moharram *et al.*, 2018; Allam *et al.*, 2018; Abou Baker 2020; Abou Baker and Rady 2020; Abou Baker *et al.*, 2020). This activity may contribute to the hypoglycaemic and hypocholesterolaemic effects of the mixture.

Conclusions

Glimepiride is an anti-diabetic sulfonylurea that in addition to its hypoglycaemic effect possesses hypocholesterolaemic and antioxidant effects. Its antioxidant effect is better than the herbal mixture. The hypoglycaemic effect of the herbal mixture aqueous extract in the present study resulted from initiating secretion of insulin from pancreatic β cells as they improved the structure of islets, and also may be due to the enhancement of peripheral metabolism of glucose.

The present study shows that the four herbs roselle, marjoram, chamomile and doum when given mixed together, have promising effects in controlling diabetic hyperglycaemia associated with hypercholesterolaemia, also they have a considerable antioxidant effect, which provides efficient natural supplement for controlling some metabolic disorders, in areas where these herbs are available. The effect of mixture respected the dose as the high dose effect was better than the low dose effect, i.e.: dose dependent effect. However further clinical studies should be done before their approval for use by diabetic patients.

Table 1: Effects of glimepiride and aqueous extract of the mixture, given orally daily for two successive weeks on blood glucose and alpha amylase in serum of STZ induced diabetic rats.

Parameters	Normal control	STZ (Positive control)	Glimepiride (0.1 mg/kg)	Mixture aqueous extract (250 mg/kg)	Mixture aqueous extract (500 mg/kg)
blood glucose (mg/dl)	150.23±8.13	484.25±2.86 ^a	151.84±9.43 ^b	372.19±23.14 ^{ab}	356.77±26.32 ^{ab}
α-Amylase (U/L)	463.30±51.48	1129.95±26.81 ^a	432.42±21.28 ^{ab}	1045.01±4.82 ^{ab}	1016.70±31.52 ^{ab}

Results are expressed as means ±SEM. Comparison between means was carried out using one way analysis of variance (ANOVA) followed by Tukey Kramer's multiple comparison test. N=8, p < 0.05, (a)Significant different from normal group, (b)Significant different from positive control group.

Table 2: Effects of glimepiride and aqueous extract of the mixture, given orally daily for two successive weeks on total cholesterol and HDL in serum of STZ induced diabetic rats.

Parameters	Normal control	STZ (Positive control)	Glimepiride (0.1 mg/kg)	Mixture aqueous extract (250 mg/kg)	Mixture aqueous extract (500 mg/kg)
Cholesterol (mg/dl)	191.04±4.19	265.52±2.81 ^a	234.18±2.41 ^{ab}	248.90±4.59 ^{ab}	238.93±10.36 ^{ab}
HDL-cholesterol (mg/dl)	385.00±4.35	200.75±5.50 ^a	346.23±4.55 ^{ab}	368.50±26.59 ^{ab}	543.13±15.68 ^{ab}

Results are expressed as means ±SEM. Comparison between means was carried out using one way analysis of variance (ANOVA) followed by Tukey Kramer's multiple comparison test. N=8, p < 0.05, (a)Significant different from normal group, (b)Significant different from positive control group.

Table 3: Effects of glimepiride and aqueous extract of the mixture, given orally daily for two successive weeks on total antioxidant capacity in serum of STZ induced diabetic rats.

Parameters	Normal control	STZ (Positive control)	Glimepiride (0.1 mg/kg)	Mixture aqueous extract (250 mg/kg)	Mixture aqueous extract (500 mg/kg)
Total antioxidant capacity (mM/L)	151.53±1.59	102.81±0.44 ^a	278.94±1.48 ^{ab}	129.55±5.45 ^{ab}	147.28±4.5 ^{ab}

Results are expressed as means ±SEM. Comparison between means was carried out using one way analysis of variance (ANOVA) followed by Tukey Kramer's multiple comparison test. N=8, p < 0.05, (a)Significant different from normal group, (b)Significant different from positive control group.

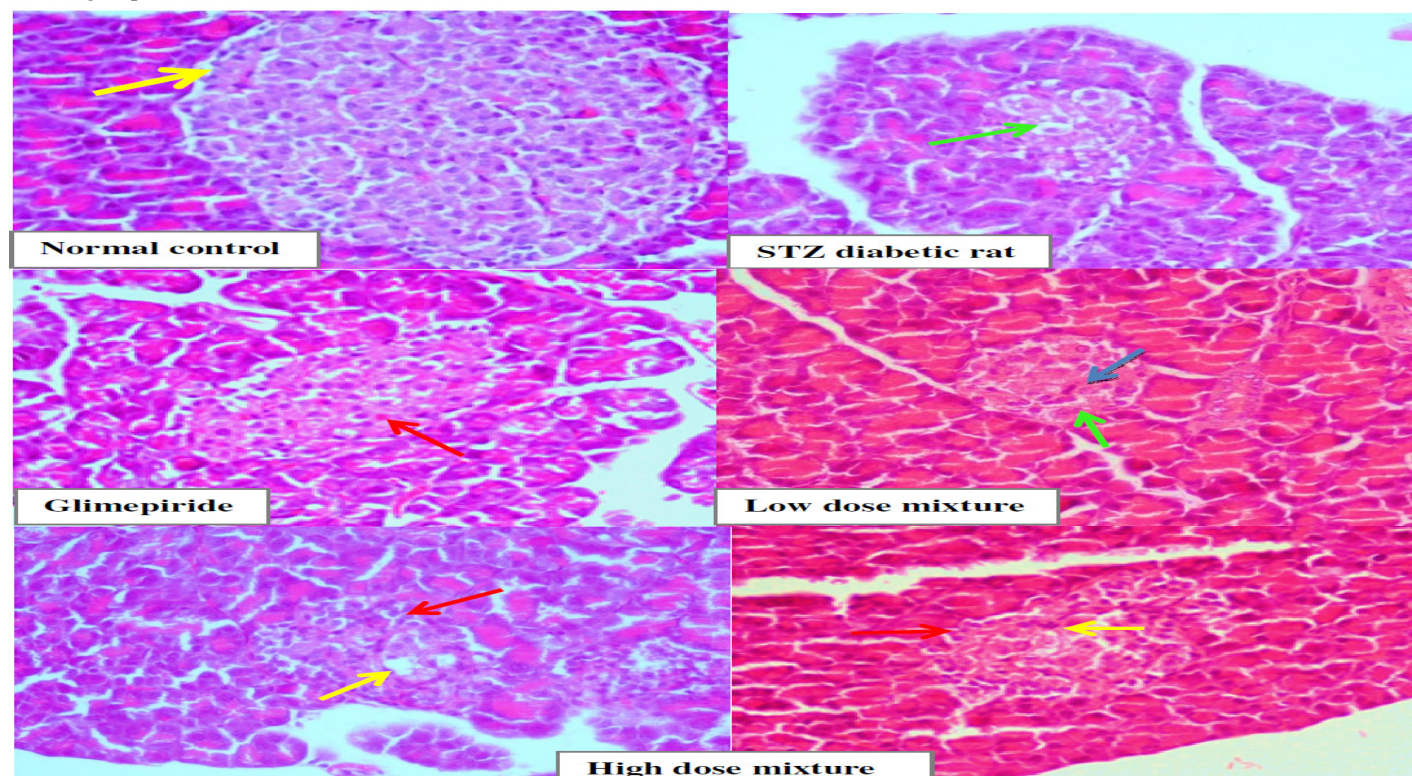


Fig1: Pancreas tissue of normal control rat showing normal islet of langerhan's, which are well defined, large in size, cellular and have preserved organized architecture [yellow arrow] [H&E X400]. Pancreatic tissue of STZ diabetic rat shows shrunken, hypocellular islet, which have irregular outline, together with disrupted architecture as well as vacuolar degeneration of cells [green arrow] [H&E X400]. Glimepiride treated pancreatic tissue shows improvement in islets size as well as cellularity [red arrow], but still not like control. [H&E X400]. Low dose mixture treated pancreatic tissue, shows shrunken islets [green arrow] together with hypocellularity as well as disrupted architecture and central necrosis [blue arrow] [H&E X400]. High dose mixture treated pancreatic tissue shows small sized islet [red arrow], which are hypocellular and have central vacuolar degeneration [yellow arrow] [H&E X400].

Conflict of Interest

The authors declare that there is no conflict of interest of any means regarding the present work

Funding

The authors didn't receive any fund from any organization for performing this work

References

- Abou Baker, D.H.; Moghazy, M. and Al-Sayed, A.A. (2020). The in vitro cytotoxicity, antioxidant and antibacterial potential of *Satureja hortensis* L. essential oil cultivated in Egypt. *Bioorg. Chem.* 103559.
- Abou Baker, D.H. and Rady, H.M. (2020). Bioassay-guided approach employed to isolate and identify anticancer compounds from *Physalis peruviana* calyces. *Plant archives*, 20: 3285-3291.
- Abou Baker, D.H. (2020). *Achillea millefolium* L. ethyl acetate fraction induces apoptosis and cell cycle arrest in human cervical cancer (HeLa) cells. *Annals of agriculture science*. In press.
- Al-Dabbagh, B.; Elhaty, I.A.; Elhaw, M.; Murali, C.; Al-Mansoori, A. and Awad, B. (2019). Antioxidant and anticancer activities of chamomile (*Matricaria recutita* L.). *BMC Res Notes.*, 12: 3.
- Allam, S.F.; Soudy, B.A.N.; Hassan, A.S.; Ramadan, M.M. and Abou Baker D.H. (2018). How do mentha plants induce resistance against *Tetranychus urticae* (Acari: Tetranychidae) in organic farming?. *Journal of Plant Protection Research*, 5(3): 265 275.
- Aremu, A. and Fadele, O.K. (2011). Study of some properties of doum palm fruit [*Hyphaene thebaica* Mart.] in relation to moisture content. *Afr. J. Agric. Res.*, 6: 3597-3602.
- Bernfeld, P. (1995). Alpha, and beta amylases. *Methods Enzymol.*, 1: 149-151.
- Cho, N.; Shaw, J.; Karuranga, S.; Huang, Y.; da Rocha, F.J. and Ohlrogge, A. (2018). Diabetes atlas: global estimates of diabetes prevalence for 2017 and projections for 2045. *Diabetes Res Clin Pract.* 138: 271–81.
- Drury, R.A.; Wallington, E.A. and Cancerson, R. (1976). *Carlton's Histopathological Techniques*. 4th Edition. Oxford University Press, Oxford, London, New York.
- El-Gengaihi, S.E.; Arafa, M.M.; Abou Baker, D.H.; Shoaib, R.M.; Asker, M.S.; Abdelhamid, S.A. and Hassan, E.M. (2020). Chemical, Biological and Molecular studies on different Citrus species wastes. *Plant archives*, 20(1): 2773-2782.
- El-Gengaihi, S.E.; Mossa, A.T.H.; Refaie, A.A. and Abou Baker, D.H. (2016a). Hepatoprotective efficacy of *Cichorium intybus* L. extract against carbon tetrachloride-induced liver damage in rats. *J Diet Suppl.*, 13: 570-584.
- El-Gengaihi, S.E.; Hamed, M.A.; Abou Baker D.H. and Mossa, A.T. (2016b). Flavonoids from sugar beet leaves as hepatoprotective agent. *Int J Pharm Pharm Sci.*, 8: 281-286.
- Gundala, N.K.V.; Naidu, V.G.M. and Das, U.N. (2018). Amelioration of streptozotocin-induced type 2 diabetes mellitus in Wistar rats by arachidonic acid. *Biochem Biophys Res Commun.*, 496(1): 105-113.
- Hamilton, J.S.; Powell, L.A.; McMaster, C.; McMaster, D. and Trimble, E.R. (2003). Interaction of glucose and long chain fatty acids [C18] on antioxidant defences and free radical damage in porcine vascular smooth muscle cells in vitro. *Diabetologia*, 46(1): 106-114.
- Ibrahim, E.A.; Abou Baker, D.H. and El-Baz, F.K. (2016). Anti-Inflammatory and Antioxidant Activities of Rhubarb Roots Extract. *Int J Pharm Sci Rev Res.*, 17: 93-99.
- Jung, U.J. and Choi, M.S. (2014). Obesity and its metabolic complications: the role of adipokines and the relationship between obesity, inflammation, insulin resistance, dyslipidemia and nonalcoholic fatty liver disease. *Int J Mol Sci.*, 15: 6184–6223.
- Kamalakkannan, N. (2006). Prince PS. Antihyperglycaemic and antioxidant effect of rutin, apolyphenolic flavonoid, in streptozotocin-induced diabetic wistar rats. *Basic Clin. Pharmacol Toxicol.*, 98(1): 97-103.
- Kamel, M.A. (2014). Protective effects of Marjoram oil (*Organium majorana* L.) on Antioxidant enzymes in Experimental Diabetic Rats. *Assiut Vet Med J.*, 60: 68-75.
- Koracevic, D.; Koracevic, G.; Djordjevic, V.; Andrejevic, S. and Cosic, V. (2001). Method for the measurement of antioxidant activity in human fluids. *J Clin Pathol.*, 54: 356-361.
- Maged, M.Y. and Saleh, N.M. (2007). Protective Potential of Glimpiride and Nerium oleander Extract on Lipid Profile, Body Growth Rate, and Renal Function in Streptozotocin-Induced Diabetic Rats. *Turk J Biol.*, 31: 95-102.
- Mardiah, Zakaria, F.R.; Prangdimurti, E. and Damanik, R. (2014). The Effect Of Roselle Extract [*Hibiscus sabdariffa* Linn.] On Blood Glucose Level And Total Antioxidant Level On Diabetic Rat Induced By Streptozotocin. *IOSR J Pharm.* [IOSRPHR], 4: 08-16.
- Mir, S.H.; Darzi, M.M.; Ahmad, F.; Chishti, M.Z. and Mir, M.S. (2008). The influence of glimepiride on the biochemical and histomorphological features of streptozotocin-induced diabetic rabbits. *Pak J Nutr.*, 7(3): 404-407.
- Mohamed, W.R.; Sherbiny, E.G.A.; Zaki, H.F. and Sayed, E.M.E. (2012). Modulation of the antidiabetic effect of glimepiride by diazepam in diabetic rats. *Br. J. Pharmacol. Toxicol.*, 3(5): 190-196.
- Moharram, F.A.E.; Al-Gendy, A.A.; El-Shenawy, S.M.; Ibrahim, B.M. and Zarka, M.A. (2018). Phenolic profile, anti-inflammatory, antinociceptive, anti-ulcerogenic and hepatoprotective activities of *Pimentaracemosa* leaves. *BMC Complement Altern Med.*, 18: 208
- Mossa, A.T.H.; Ibrahim, F.M.; Mohafrash, S.M.; Abou Baker, D.H. and El-Gengaihi, S. (2015). Protective effect of ethanolic extract of grape pomace against the adverse effects of cypermethrin on weanling female rats. *Evid Based Complement Alternat Med*, 1-10.
- Mostafa, R.E.; Ibrahim, B.M.M. and Abdel Jaleel, G.A. (2016). Neuro-protective effects of *Ginkgo biloba* leaves extract on cerebral ischemia-reperfusion injury induced experimentally in ovariectomized rats. *Int J Pharm Pharm Sci.*, 8(8): 237-242.
- NIH Publications No. 8023, revised 1978.
- Ortega, Á.; Berná, G.; Rojas, A.; Martín, F. and Soria, B. (2017). Gene-Diet Interactions in Type 2 Diabetes: the Chicken and Egg Debate. *Int J Mol Sci.*, 18(6): E1188.

- Ramesh, B. and Pugalendi, K.V. (2006). Impact of umbelliferone [7- hydroxycoumarin] on hepatic marker enzymes in Streptozotocin diabetic rats. *Indian J Pharmacol.* 38: 209-210.
- Salam, M.A.; Ibrahim, B.M.M.; El-Batran, S.; El-Gengaihi, S.E. and Abou Baker, D.H. (2016). Study of the possible antihypertensive and hypolipidemic effects of an herbal mixture aqueous extract on L-name-induced hypertensive rats. *Asian J Pharm Clin Res.*, 9: 85-90.
- Salama, A.A.A.; Ibrahim, B.M.M; Yassin, N.A.; Mahmoud, S.S.; Gamal, El-Din A.A. and Shaffie, N.A. (2017). Regulatory Effects of Morusalba Aqueous Leaf Extract in Streptozotocin-Induced Diabetic Nephropathy. *Der Pharma Chem.*, 9(1): 46-52.
- Trinder, P. (1969). Determination of Glucose in Blood using Glucose Oxidase with an alternative oxygen acceptor. *Ann Clin. Biochem.* 6: 24-27.
- Ulewicz-Magulska, B.; Wesolowski, M. (2019). Total Phenolic Contents and Antioxidant Potential of Herbs Used for Medical and Culinary Purposes. *Plant Foods Hum Nutr.*, 74: 61–67.