



# Plant Archives

Journal homepage: <http://www.plantarchives.org>  
doi link : <https://doi.org/10.51470/PLANTARCHIVES.2021.v21.S1.268>

## EFFECTS OF THYROID DYSFUNCTION ON LIVER TISSUE IN MALE RATS

Mohammed S. Hadi\* and Ekhlas A. Hamza

Dept. of Anatomy and Histology, College of veterinary medicine, Al-Qasim Green University, Iraq

\*Corresponding Author E-mail: mohammedmsc993@gmail.com

### ABSTRACT

Forty males Wistar rats about 5 months old with average weight  $250 \pm 10$  gm were divided randomly into four equal groups and treated for 3 months as following: First group (C) was given normal saline (0.09%) NaCl only as a control group. Second group (T1) was given Levothyroxine (LRX) ( $100 \mu\text{g}/\text{kg}$  b.w I/P). Third group (T2) was given Carbimazole (CBZ) ( $5 \text{ mg}/\text{kg}$ ). And fourth group was given mixed dose were given LRX ( $50 \mu\text{g}/\text{kg}$  b.w I/P) for 6 weeks and then given CBZ for other 6 weeks at dose ( $2.5 \text{ mg}/\text{kg}$  b.w orally). At the end of the experiment, all animals were sacrificed and the weight of animal were taken, then blood samples were collected directly from the heart and serum samples were isolated to measure T3, T4 and TSH hormone. Samples of liver and thyroid gland were taken for histological study. The results of T3 hormones revealed a significant ( $P < 0.05$ ) decrease in serum T3 level in Carbimazole treated groups when compared with the control and levothyroxine-treated rats. On the other hand, levothyroxine caused a significant ( $P < 0.05$ ) increase in serum T3 level when compared with the control group. The results of T4 hormones reveals a significant ( $P < 0.05$ ) decrease in serum T4 level in Carbimazole treated groups when compared with the control group and levothyroxine-treated rats. While, levothyroxine caused a significant ( $P < 0.05$ ) increase in serum T4 level when compared with the control groups. For TSH hormones, the results showed there were a significant ( $P < 0.05$ ) rise in serum TSH level in Carbimazole treated groups when compared with the control group and levothyroxine-treated groups. While, levothyroxine caused a significant ( $P < 0.05$ ) decrease in serum TSH level when compared with the control groups. The histological sections for liver in control group revealed normal liver parenchyma and normal hepatocytes and sinusoids. Thyroid gland sections show there was normal histological structures. In T1 group, Liver sections showed there was single cell necrosis with focal mononuclear cells aggregation. Thyroid gland sections showed there was hyperthyroidism characterize by increase in the colloid resorption with vacuolation of the nuclei of epithelial cells that lining the follicles. In T2 group, Liver sections show there was apoptosis in hepatocyte with increase in the number of kupffer cells. Thyroid gland sections show there was hypothyroidism with congestion in the blood vessels. In T3, Liver sections show there was no clear lesion. Thyroid gland sections show there was active thyroid follicles with presence of resorption vacuoles and congestion blood vessels.

**Keywords:** Levothyroxine, Carbimazole, Thyroid dysfunction, T3, T4, TSH hormone, Liver histology, Thyroid histology.

### Introduction

The thyroid gland is the main component of thyroid hormone system, which secretes thyroid hormones by the stimulation of TSH secreted from pituitary gland. The thyroid gland plays a very important role in the metabolism, growth, and maturation of the body. By producing the steady amount of thyroid hormones, thyroid gland also helps to regulate many functions of the body (Mullur and Brent, 2014). The mature thyroid gland contains numerous follicles composed of thyroid follicular cells that surround secreted colloid, a proteinaceous fluid that contains large amounts of thyroglobulin, the protein precursor of thyroid hormones (Jameson & Weetman, 2015). Thyroid gland is specialized for production, storage and release of thyroid hormones, thyroxine (T4) and triiodothyronine (T3). These hormones are the only iodine-containing amine hormones in the vertebrate and are necessary for optimal growth, development, and function of tissues (Köhrle, 2018). Thyroxine (T4) is a pro-hormone, which must be converted to tri-iodothyronine (T3), which takes place primarily in the

liver and kidney (Rajab *et al.*, 2017). Thyroid hormones are involved in regulation of metabolic rate and energy expenditure in homeothermic animals and they are necessary for normal cell growth and development. Also, have vital influence on oxygen consumption and metabolic rate of all cells including hepatocytes, thus alter hepatic function. The liver in turn metabolizes thyroid hormones through conjugation, excretion, peripheral de-iodination, and in the synthesis of thyroid-binding globulin, and thus controls their endocrine effects (Martínez *et al.*, 2014). Thyroid disorder is a general term representing several different diseases involving thyroid hormones and the thyroid gland. Thyroid disorders are commonly separated into two major categories, hyperthyroidism and hypothyroidism, depending on whether serum thyroid hormone levels (T4 and T3) are increased or decreased, respectively (Beld *et al.*, 2015). Hyperthyroidism, excess thyroid hormone, promotes a hypermetabolic state characterized by increased resting energy expenditure, weight loss, reduced cholesterol levels, increased lipolysis, and gluconeogenesis. Conversely, hypothyroidism, reduced

thyroid hormone levels, is associated with hypometabolism characterized by reduced resting energy expenditure, weight gain, increased cholesterol levels, reduced lipolysis, and reduced gluconeogenesis (McAninch & Bianco, 2014). Hypothyroidism is a common endocrine disorder resulting from deficiency of thyroid hormone. It is often the primary process in which the thyroid gland produces insufficient amounts of thyroid hormone. It can also be secondary, i.e., lack of thyroid hormone secretion due to the failure of either adequate thyrotropin (TSH) secretion from the pituitary gland or thyrotropin-releasing hormone (TRH) from the hypothalamus (secondary or tertiary hypothyroidism) (Katz *et al.*, 2017). In primary hypothyroidism the loss of thyroid function/tissue results in increased TSH secretion which promotes goiter formation and secondary hypothyroidism may be caused by insufficient stimulation of the thyroid from hypothalamic (decreased TRH secretion) or pituitary (decreased TSH secretion) disease, or peripheral resistance to thyroid hormones. Hypothyroidism involves every organ in the body and so can produce dozens of signs and symptoms, many of which mimic those of other diseases. Furthermore, a variety of factors can influence the presentation of hypothyroidism. Prominent among these are disease stage, severity and the patient's age (Lovely, 2018).

**The present study is carried out the aim to** determine the effect of thyroid dysfunction on the histological changes on thyroid and liver of male rats.

### Materials and Methods

#### Experimental design

Forty males Wistar rats about 5 months old with average weight  $250 \pm 10$  gm were divided randomly into four equal groups and treated for 3 weeks as following: First group (C) was given normal saline (0.09%) NaCl only as a control group. Second group (T1) was given Levothyroxine (LRX) ( $100 \mu\text{g}/\text{kg}$  b.w I/P). Third group (T2) was given Carbimazole (CBZ) ( $5 \text{ mg}/\text{kg}$ ). And fourth group was given mixed dose were given LRX ( $50 \mu\text{g}/\text{kg}$  b.w I/P) for 6 weeks and then given CBZ for other 6 weeks at dose ( $2.5 \text{ mg}/\text{kg}$  b.w orally). At the end of the experiment, all animals were sacrificed and the weight of animal were taken, then blood samples were collected directly from the heart and serum samples were isolated to measure T3, T4 and TSH hormone by using ELISA technique. Samples of liver and thyroid gland were taken for histological study.

#### ELISA Assay for Determination of Rat T4 Level, TSH Level and T3 Level:

ELISA assay was achieved according to the method described by the manufacturing company (Elabscience /USA).

#### Histological Studies

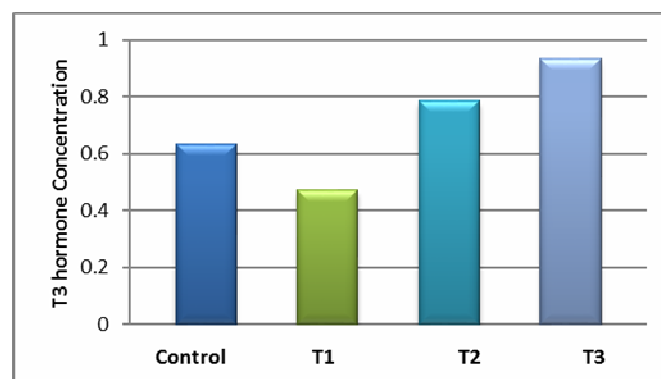
The histological sections of the thyroid gland, liver and kidney that were included in the study were prepared following the steps described by (Bancroft & Layton, 2012).

### Results and Discussion

#### Triiodothyronine (T3) concentration

By using ELISA technique, the levels of Thyroid hormone concentrations were measured in the treated group and in the control groups.

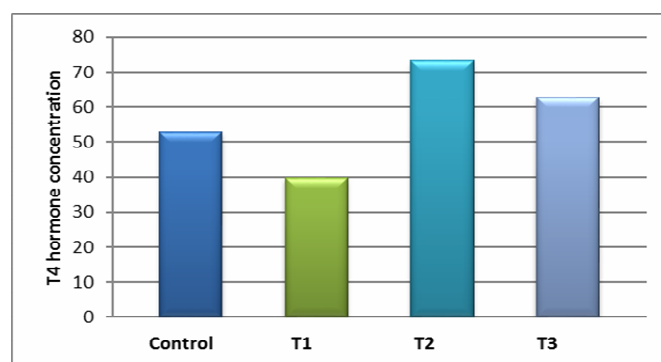
The mean of level of T3 hormone in T1 group which given levothyroxine ( $100 \mu\text{g}/\text{kg}$  b.w I/P) was ( $0.786 \pm 0.02$ ), T2 group which given carbimazole ( $5 \text{ mg}/\text{kg}$ ) was ( $0.472 \pm 0.01$ ) and T3 which given mix of levothyroxine and carbimazole ( $50 \mu\text{g}/\text{kg}$  b.w I/P +  $2.5 \text{ mg}/\text{kg}$  b.w orally) was ( $0.934 \pm 0.07$ ), while in C group was ( $0.634 \pm 0.04$ ). This study reveals a significant ( $P < 0.05$ ) decrease in serum T3 concentration in Carbimazole treated groups when compared with the control and levothyroxine-treated rats. On the other hand, levothyroxine caused a significant ( $P < 0.05$ ) increase in serum T3 concentration when compared with the control groups. Figure (1) show these results.



**Fig. 1 :** Triiodothyronine hormones levels

#### Thyroxine (T4) concentration

The mean of level of T4 hormone in T1 group which given levothyroxine ( $100 \mu\text{g}/\text{kg}$  b.w I/P) was ( $73.32 \pm 1.18$ ), T2 group which given carbimazole ( $5 \text{ mg}/\text{kg}$ ) was ( $39.76 \pm 1.53$ ) and T3 which given mix of levothyroxine and carbimazole ( $50 \mu\text{g}/\text{kg}$  b.w I/P +  $2.5 \text{ mg}/\text{kg}$  b.w orally) was ( $62.76 \pm 2.30$ ), while in Control group was ( $53.06 \pm 3.35$ ). This study reveals a significant ( $P < 0.05$ ) decrease in serum T4 concentration in Carbimazole treated groups when compared with the control group and levothyroxine-treated rats. While, levothyroxine caused a significant ( $P < 0.05$ ) increase in serum T4 concentration when compared with the control groups. Figure (2) illustrate these results.



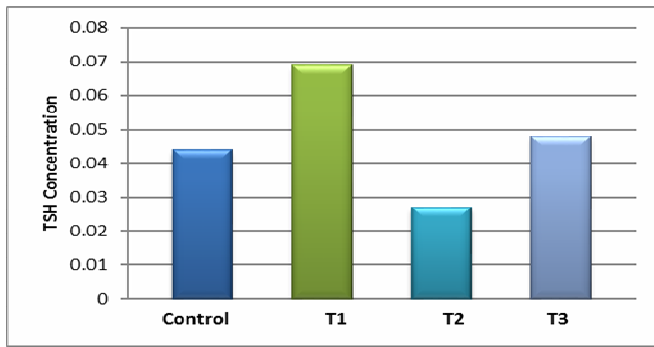
**Fig. 2 :** Thyroxine hormones levels

#### Thyroid Stimulating Hormone (TSH)

The mean of level of T4 hormone in T1 group which given levothyroxine ( $100 \mu\text{g}/\text{kg}$  b.w I/P) was ( $0.069 \pm 0.01$ ), T2 group which given carbimazole ( $5 \text{ mg}/\text{kg}$ ) was ( $0.027 \pm 0.01$ ) and T3 which given mix of levothyroxine and carbimazole ( $50 \mu\text{g}/\text{kg}$  b.w I/P +  $2.5 \text{ mg}/\text{kg}$  b.w orally) was ( $0.048 \pm 0.01$ ), while in Control group was ( $0.044 \pm 0.01$ ). This study reveals a significant ( $P < 0.05$ ) rise in serum TSH concentration in Carbimazole treated groups when compared with the control group and levothyroxine-treated groups.



While, levothyroxine caused a significant ( $P < 0.05$ ) decrease in serum TSH concentration when compared with the control groups. Figure (3) show these results.



**Fig. 3 :** Thyroid Stimulating Hormone levels

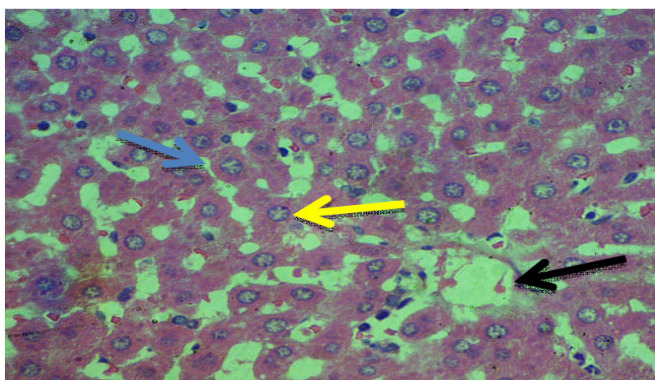
Result in this study was in accordance with study by (Abraham *et al.*, 2015) and (Mondal & Mugesh, 2017) who observed that Carbimazole has an anti-thyroidal property, which inhibit TPO enzyme activities. It might also reduce  $T_4$  level by increasing the level of iodine in circulation, which will inhibit the thyroid gland activity by decreasing iodide organification and release of  $T_3$  and  $T_4$ .

Result in this study regarded the levothyroxine was in accordance with study by (Uduak *et al.*, 2014) who found that LVT significantly reduced TSH while increasing  $T_3$  and  $T_4$  level. LVT is identical to that produced naturally in the thyroid gland. It acts like the endogenous thyroid hormone thyroxine,  $T_4$ . In the liver and kidney,  $T_4$  is converted to  $T_3$ , an active metabolite. Thyroxine ( $T_4$ ) is the form of thyroid hormone that is solely secreted by the thyroid gland while about 80% of  $T_3$ , which is the biologically active thyroid hormone in circulation, is formed by the de-iodination of  $T_4$ .  $T_3$  produced by the thyroid gland is also in small quantity, it has a rapid onset of action and metabolises quickly, thereby accelerating its elimination rate when compared with  $T_4$ .

**Histological Study**

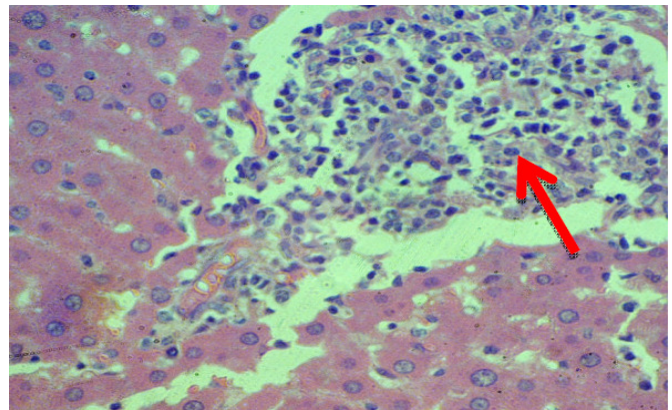
**Liver:**

Liver sections of rats in control group show there was normal liver parenchyma and normal hepatocytes and sinusoids ( Fig 4).



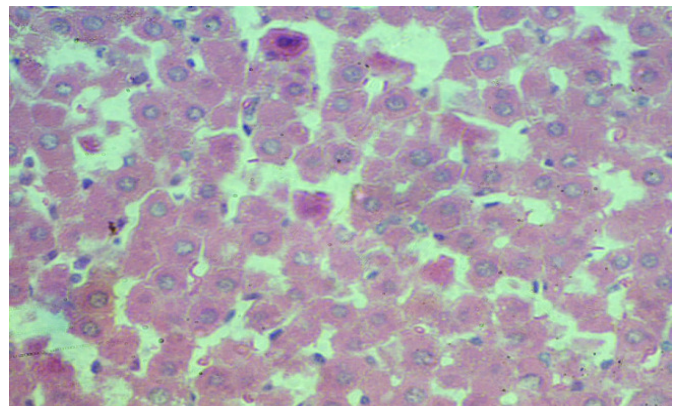
**Fig. 4 :** Cross section of rat liver in control group. Showed normal liver parenchyma with normal sinusoids(blue arrow),central vein(black arrow), and kupffer cell (yellow arrow).400X (H&E stain).

Liver sections of rats in T1 group which given levothyroxine (100  $\mu\text{g}/\text{kg}/\text{b.w}$  I/P) showed there was single cell necrosis with focal mononuclear cells aggregation (Fig. 5).



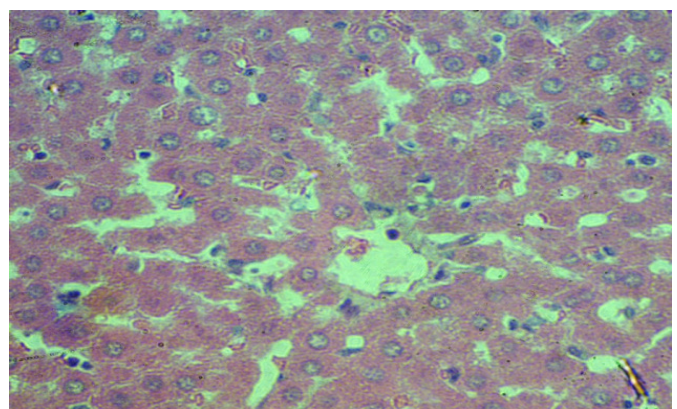
**Fig. 5 :** Cross section of rat liver in T1 group treated with levothyroxine (100  $\mu\text{g}/\text{kg}$  b.w I/P). Showed single cell necrosis with focal mononuclear cells aggregation (red arrow). (H&E 200X).

Liver sections of rats in T2 group which given carbimazole (5 mg/kg) show there was apoptosis in hepatocyte with increase in the number of kupffer cells (H&E 400X) (Fig 6).



**Fig. 6 :** Cross section of rat liver in T2 group treated with carbimazole(5mg/kg).Showed apoptosis in hepatocyte(black arrow with increase in the number of kupffer cells (red arrow).(H&E 200X).

Liver sections of rats in T3 group which given mix of levothyroxine and carbimazole (50  $\mu\text{g}/\text{kg}$  b.w I/P+2.5 mg /kg b.w orally), show there was no clear lesion (H&E 400X) (Fig 7).



**Fig. 7 :** Cross section of rat liver in T3 group treated with mix of levothyroxine and carbimazole (50  $\mu\text{g}/\text{kg}$  b.w I/P+2.5 mg /kg b.w orally).Showed no clear lesion (H&E 400X).

The histological sections of rats liver in T1 group which given levothyroxine (100  $\mu\text{g}/\text{kg}$  b.w I/P) revealed a single cell necrosis with focal mononuclear cells aggregation. This result leads to conclusion that the hyperthyroidism clearly



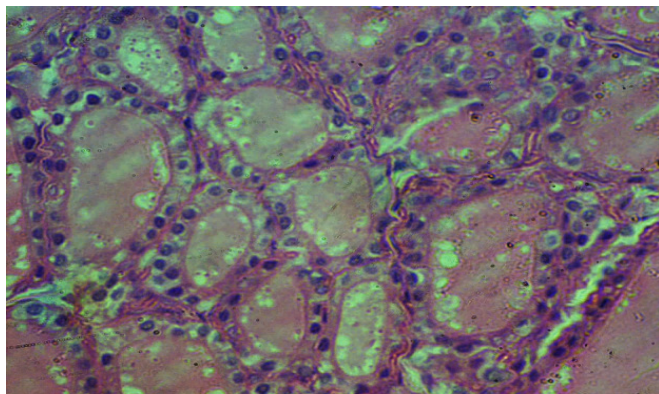
effect on the liver tissues (Al-Naely & Shattnan, 2017). Result in this study was in accordance with study by (Demir *et al.*, 2016 and MoKim *et al.*, 2012), who reported that levothyroxine lead to congestion and hyperplasia of the bile duct and aggregation of inflammatory cells with simple degeneration and cell necrosis.

The histological sections of rats liver in T2 group which is given carbimazole(5mg/kg)show there was apoptosis in hepatocyte with increase in the number of kupffer cells. The results was in agreement with the results of (Hashem *et al.*,2016 and Kanel,2017).who reported that carbimazole lead to clear apoptosis in hepatic cells and hyperplasia of the bile duct, congestion in the central vein and infiltration of inflammatory cells.

The histological sections of rats liver in T3 group which is given mix of levothyroxine and carbimazole (50 µg/kg b.w I/P+2.5 mg /kg b.w orally).Showed there was no clear lesion. The results was in agreement with the results of (Siddiqui *et al.*,2015) who reported that the use of combinational therapy of levothyroxine and carbimazole lead to control disturbed levels of thyroid hormones and better performance of the liver and kidney.

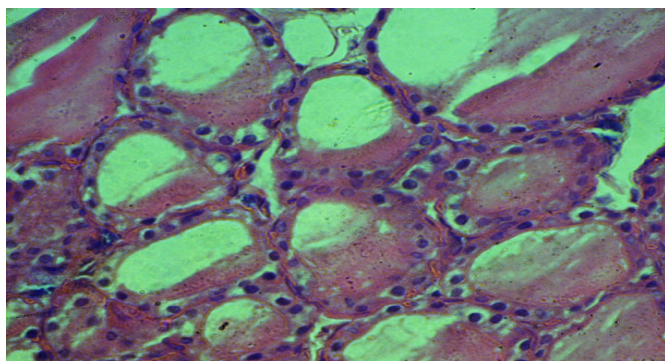
### Thyroid gland

Thyroid gland sections of rats in control group show there was normal histological structures (Fig. 8).



**Fig. 8 :** Cross section of rat liver in control group. Showed normal histological structures 400X(H&E stain).

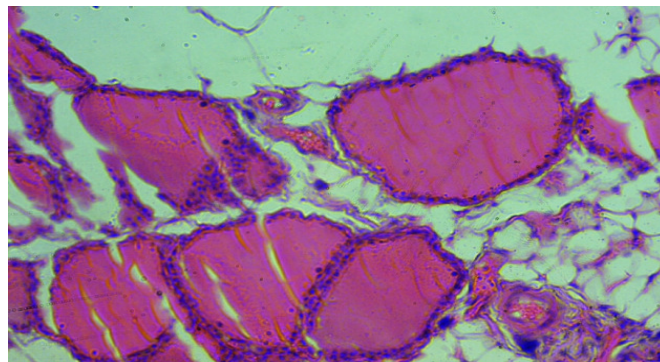
Thyroid gland sections of rats in T1 group which given levothyroxine (100 µg/kg b.w I/P) showed there was hyperthyroidism characterize by increase in the colloid resorption (note multiple follicles that appear have little or without colloid) with vacuolation of the nuclei of epithelial cells that lining the follicles (Fig. 9).



**Fig. 9 :** Cross section of rat thyroid gland in T1group treated with levothyroxine (100 µg/kg b.w I/P). Showed hyperthyroidism characterize by increase in the colloid resorption (note multiple

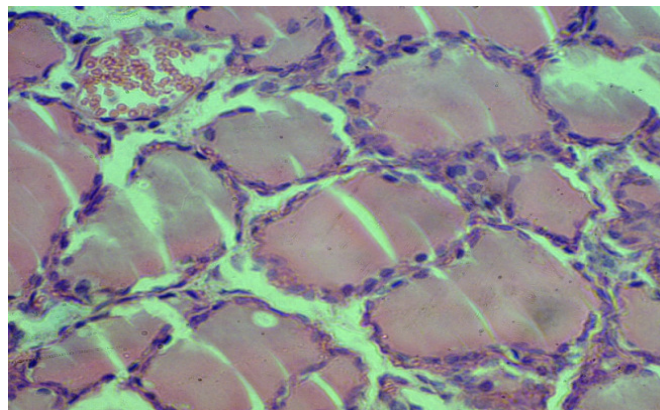
follicles that appear have little or without colloid) with vacuolation of the nuclei of epithelial cells that lining the follicles. (H&E 400X).

Thyroid gland sections of rats in T2 group which given carbimazole (5mg/kg)show there was hypothyroidism characterize by decrease in the colloid resorption (note absences of resorption vacuoles) with congestion in the blood vessels (H&E 400X) (Fig 10).



**Fig. 10 :** Cross section of rat thyroid gland in T2 group treated with carbimazole(5mg/kg). Showed hypothyroidism characterize by decrease in the colloid resorption (note absences of resorption vacuoles ) with congestion in the blood vessels (H&E 400X).

Thyroid gland sections of rats in T3 group which given mix of levothyroxine and carbimazole (50 µg/kg b.w I/P+2.5 mg /kg b.w orally), show there was active thyroid follicles with presence of resorption vacuoles and congestion blood vessels (H&E 400X) (Fig 11).



**Fig. 11 :** Cross section of rat thyroid gland in T3 group treated with mix of levothyroxine and carbimazole (50 µg/kg b.w I/P+2.5 mg /kg b.w orally). Showed active thyroid follicles with presence of resorption vacuoles and congestion blood vessels (.H&E 400X).

The histological sections of rats thyroid gland in T1group which given levothyroxine (100 µg/kg b.w I/P) revealed hyperthyroidism characterize by increase in the colloid resorption (note multiple follicles that appear have little or without colloid) with vacuolation of the nuclei of epithelial cells that lining the follicles. Result in this study was in accordance with study by (Mohamedali *et al.*, 2015), who reported that levothyroxine lead an apparent increase in follicle size, which exhibited peripheral colloidal vacuolations with vacuolation of the nuclei of epithelial cells that lining the follicles and dilated congested blood vessels.

The histological sections of rats thyroid gland in T2 group which is given carbimazole (5mg/kg) show there was hypothyroidism characterize by decrease in the colloid resorption (note absences of resorption vacuoles) with congestion in the blood vessels. The results was in agreement

with the results of (Zaidi *et al.*, 2014 and Ahmed, 2019) who reported that mention that carbimazole which is anti-thyroid drug inhibit the formation of T3 and T4, which stimulate the anterior pituitary gland to secrete more TSH and this hormone stimulate the growth of thyroid gland, results hyper atrophy of follicular epithelium.

The histological sections of rats thyroid gland in T3 group which is given mix of levothyroxine and carbimazole (50 µg/kg b.w I/P+2.5 mg /kg b.w orally). Showed there was active thyroid follicles with presence of resorption vacuoles and congestion blood vessels. The results was in agreement with the results of (Siddiqui *et al.*, 2015) who reported that the use of combinational therapy of levothyroxine and carbimazole lead control disturbed levels of thyroid hormones and better performance of the liver and kidney.

### Conclusions

From this study, it was found that, There was decrease in the Levels of T3 and T4 hormone with increase in the Levels of TSH hormone in the Carbimazole treated groups. Levothyroxine lead to increase in the Levels of T3 and T4 hormone with a decrease in the Levels of TSH hormone. Thyroid disorder hypo- Hyperthyroidism and its treatments drugs Carbimazole and levothyroxine have led to histological changes in the liver.

### References

- Abraham, P.; Avenell, A.; Park, C.M.; Watson, W.A.; Bevan, J.S. (2015). A systematic review of drug therapy for Graves' hyperthyroidism. *Eur J Endocrinol.* 153(4): 489-498.
- Ahmed, O.H. (2019). Carbimazole and its effects on thyroid gland of female rabbits *J. Pharm. Sci. & Res.* 11(4): 1610-1613.
- Al-Naely, A. and Shattnan, D. (2017). Effect of grape seed extract on biochemical factor and histological changes in liver and the kidney in albino rat infected hypo-hyperthyroidism induced laboratory by carbimazole and l-thyroxine. *Journal of Global Pharma Technology*, 9(9): 174-181.
- Bancroft, J.D. and Layton, C. (2012). The hematoxylin and eosin. *Bancroft's Theory and Practice of Histological Techniques*, 173-186.
- Demir, F.; Ünübol, M.; Aypak, S.U.; Epek, E.; Akta, G.S.; Ekren, G.S.; Ilmaz, M.Y.; Tunca, R. and Güney, E. (2016). Histopathologic Evaluation of Nonalcoholic Fatty Liver Disease in Hypothyroidism-Induced Rats. *Journal of Endocrinology.* 50(83): 3-7.
- Hashem, H.A.; El-Metwaly, H.; Mobarak, Y. M.; & Ibrahim, Z. N. (2016). Impact of Induced Thyroxine and Carbimazole Vacillation on Liver of Female Rats. *Egyptian Academic Journal of Biological Sciences, D. Histology & Histochemistry*, 8(2):15-29.
- Jameson, J.L. and Weetman, A. P. (2015). Disorders of the thyroid gland. *Harrisons principles of internal medicine*, 2(8): 2060-2083.
- Kanel, G.C. (2017). Histopathology of drug-induced liver disease. *Drug induced liver disease*, 28(33): 237-289.
- Katz, A.I.; Emmanouel, D.S. and Lindheimer, M.D. (2017). Thyroid hormone and the kidney. *Nephron.* 15(5): 223-249.
- Köhrle, J. (2018). Thyroid hormones and derivatives: endogenous thyroid hormones and their targets. In *Thyroid Hormone Nuclear Receptor* (pp. 85-104). Humana Press, New York, NY.
- Lovely, N.S. (2018). Effect of hypothyroidism on the cardiovascular system: A review. *Mainamoti Medical College Journal.* 27(13): 15-19.
- Martínez-Sánchez, N.; Alvarez, C.V.; Fernø, J.; Nogueiras, R.; Diéguez, C. and López, M. (2014). Hypothalamic effects of thyroid hormones on metabolism. *Best Practice & Research Clinical Endocrinology & Metabolism*, 28(5): 703-712.
- McAninch, E.A. and Bianco, A.C. (2014). Thyroid hormone signaling in energy homeostasis and energy metabolism. *Annals of the New York Academy of Sciences*, 1311, 77.
- Mohamedali, M.; Reddy Maddika, S.; Vyas, A.; Iyer, V. and Cheriya, P. (2015). Thyroid disorders and chronic kidney disease. *International journal of nephrology*, 52(28): 57-61.
- MoKim, S.; ChanKim, S.; Chung, I.K.; Cheon, W.H. and Ku, S.K. (2012). Antioxidant and Protective Effects of *Bupleurumfalcatum* On the l-Thyroxine-Induced Hyperthyroidism in Rats. *Journal of Hepatology.* 57(84): 97-112.
- Mondal, S. and Muges, G. (2017). Novel thyroid hormone analogues, enzyme inhibitors and mimetics, and their action. *Molecular and cellular endocrinology*, 458: 91-104.
- Mullur, R.; Liu, Y.Y. and Brent, G.A. (2014). Thyroid hormone regulation of metabolism. *Physiol Rev* 94(2): 355-382.
- Rajab, N.M.A.; Ukropina, M. and Cacic-Milosevic, M. (2017). Histological and ultrastructural alterations of rat thyroid gland after short-term treatment with high doses of thyroid hormones. *Saudi journal of biological sciences*, 24(6): 1117-1125.
- Siddiqui, M.F.; Anwer, H.; Batool, Z.; Hasnain, S.; Imtiaz, M.; Tasneem, A. and Alam, R. (2015). Assessment of carbimazole, propylthiouracil & l-thyroxine for liver markers in thyroid patients from punjab, pakistan. *J App Pharm.* 7(1): 105-113.
- Uduak, O.A.; Ani, E.J.; Etoh, E.C.I. and Macstephen, A.O. (2014). Comparative effect of *Citrus sinensis* and carbimazole on serum T4, T3 and TSH levels. *Nigerian medical journal: journal of the Nigeria Medical Association*, 55(3): 230-237.
- Van den Beld, A.W.; Visser, T.J.; Feelders, R.A.; Grobbee, D.E.; and Lamberts, S.W. (2015). Thyroid hormone concentrations, disease, physical function, and mortality in elderly men. *The Journal of Clinical Endocrinology & Metabolism.* 90(12): 6403-6409.
- Zaidi, T.M.; Khan, A.A.; Hasan, B.M. and Faruqi, A.N. (2014). Carbimazole induced thyroid histopathology in Albino rats during development. *J Anat Soc India*, 53(2): 14-17.