



## ROLE OF REPRODUCTIVE HORMONES IN OVARIAN PATHOLOGY IN COWS

Pankratova A.V.<sup>1</sup>, Aminova A.L.<sup>2</sup>, Kozyrev S.G.<sup>3</sup> and Al-Azawi Nagham M.H.<sup>4,5</sup>

<sup>1</sup>Federal State Educational Institution of Higher Professional Education Moscow State Academy of Veterinary Medicine and Biotechnology named after K. I. Skryabin, Russia.

<sup>2</sup>Bashkir State agricultural Institute, Russia.

<sup>3</sup>Department of Normal and Pathological Anatomy and Animal Physiology, Gorsky State Agrarian University, Vladikavkaz, Russia.

<sup>4</sup>Department of Crop Science, Agricultural Engineering Sciences Collage, University of Baghdad, Iraq.

<sup>5</sup>Peoples' Friendship University of Russia, Russia.

Corresponding author: naghamalazawi@yahoo.com ; soslan-k72@mail.ru

### Abstract

Ovarian cysts are one of the most common pathologies that are characteristic of cows of all ages, but more often in the second to fifth lactations, 1-4 months after calving and cause significant damage due to the increase in the interwell interval, an average of 22-64 days or more. For the treatment of cows with ovarian cysts steroid hormones are shown, serum gonadotropin preparations and to placental row, synthetic analogues of GnRH and synthetic analogs of prostaglandins. It is generally recognized that disruption of the normal endocrine balance plays a major and initial role in the development of cysts. It is proved that in the early postpartum period about 25% of cows with cysts had subluteal level peripheral blood progesterone concentrations launcher mechanism of formation of persistent follicles with further transformation into follicular cysts. Disruption of the positive feedback mechanism - 17 $\beta$ -estradiol-LH precedes the formation of a persistent follicle and the formation of a follicular cyst after calving. Low levels of progesterone concentration in the peripheral blood is the main symptom and initial cause of the persistence of follicles and the appearance of cysts.

**Keywords:** ovarian cyst, persistent follicle, estradiol, progesterone, steroid hormone.

### Introduction

Spherical shape formations in the ovary tissue are generally qualified as cysts. Ovarian cysts are the one of the most common pathologies of reproductive system in dairy cow breeds especially highly productive. These pathologies are typical for cows of all ages, but more often on the second to fifth lactation, in 1-4 months after calving, during the period of the highest rise of the lactation curve (Jaskowski *et al.*, 2006) and it causes of significant harm due to prolongation of inter-calving period approximately on 22-64 days or more. A number of authors indicate higher rates, given that 60% of cows before the first ovulation after calving cystic changes in the ovaries occur unnoticed. Many of these cows are culled (Pancarci *et al.*, 2008, Cattaneo *et al.*, 2014).

Ovarian cystic formations are divided into follicular and luteal cysts. Cystic ovarian structures are distinguished as non-functioning, i.e. hormonally inactive, and functioning - hormonally active (Marelli *et al.*, 2014). Cystic ovary contains either 1-2 large spherical formations ranging in size from 15 to 22 mm or a multitude of smaller formations- from 1 to 12 mm. In that regard ovaries with cystic violations are determined as large cystic and small cystic (Marelli *et al.*, 2014; Matiller *et al.*, 2014).

For the treatment of cows with ovarian cysts steroid hormones are prescribed (Anzorov and Moryakina, 2017), gonadotropic serum and placental medication, synthetic analogues of gonadolibersins and synthetic analogues of prostaglandins are prescribed too (Eborn *et al.*, 2013; Lopez Helgueraab *et al.*, 2018).

For medical treatment of animals with follicular ovarian cysts, hormone treatments with GnRH, hCG analogues, i.e. bioregulators that induce the release of luteinizing hormone LH or have LH-like effect (Zhazhgaliyeva *et al.*, 2014; Wijma *et al.*, 2016) could be used. The use of GnRH is preferred as due to the small size of its molecules it doesn't stimulate an immune response as it may occur after hCG or LH injections (Ivanov and Gavrilov, 2015; Ivanov and Gavrilov, 2016). Cows resume normal estrous cycle within 21 days.

In some cases cows don't respond to medical treatment with GnRH (Grigorieva *et al.*, 2014), So cows are injected by human chorionic gonadotropin (hCG), which acting on the ovaries causes cyst luteinization with following increase in plasma of progesterone concentration. Then luteal cyst is lysed exposing the cow to processing with PgF<sub>2a</sub> analogues what ensures treated cows revert in 8 days (Grigorieva *et al.*, 2014).

Follicular cysts formation process hasn't been studied yet especially in the puerperal period. It is generally accepted, that the cyst is formed from a preovulatory follicle for several reasons didn't ovulate, persisted in the ovary and then inevitably complicated the impaired normal ovarian function (Kaplunov and Gavrichenko, 2017). Some researchers note that forming of follicular cysts occurs in combination with an endocrine imbalance due to the yet unidentified violations in the performance of hypothalamic-pituitary-gonadal system (Pancarci *et al.*, 2008; Cattaneo *et al.*, 2014; Zhazhgaliyeva *et al.*, 2014; Ivanov and Gavrilov, 2016). The absence or deficiency of LH preovulatory peak leads to ovulation disability and the subsequent cyst forming (Kaplunov and Gavrichenko, 2017). Hence medical treatment should be aimed for normalizing the endocrine balance based on steroid or gonadotropic concentration (LH, FSH) standardization, on control of gonadotropin-releasing factor release or on a combination of these two methods. Cysts formation is also associated with a negative ratio of progesterone concentration levels with other hormones concentration in the blood (Bisinotto *et al.*, 2014).

Ultrasound diagnosis shows that the pre-ovulatory follicle diameter of highly productive cows ranges from 16 to 20 mm (Wiltbank *et al.*, 2014; Miura *et al.*, 2015; Ribeiro *et al.*, 2012). Follicles with a diameter greater than 20 mm (Ivanov and Gavrilov, 2016; Garcia *et al.*, 2015) or 22 mm (Marelli *et al.*, 2014; Dias *et al.*, 2013) are determined as follicular ovarian cysts. However, the diameter only can't be used for accurately characterization an ovarian cyst unlike with persistent follicles. Most ovarian follicular cysts are dynamic structures that undergo constant changes (Pancarci *et al.*, 2008; Marelli *et al.*, 2014). Some researchers consider persistent follicles as the initial stage of formation of follicular cysts (Pancarci *et al.*, 2008; Miura *et al.*, 2015), others qualify persistent follicles as a separate independent follicular pathology (Ivanov and Gavrilov, 2016). Ultrasound studies have shown the result that about 21-27% of cows have cyst-like structures in the parturient period (Kaplunov and Gavrichenko, 2017, Kuzmich *et al.*, 2017) and about 50% of cysts undergo spontaneous regression before that or regress after the first unsuccessful insemination (Yusupov and Shaev, 2013). So follicular cysts formation mechanism in the ovaries within parturient period remains much like incomprehensible (Kaplunov and Gavrichenko, 2017; Kuzmich *et al.*, 2017).

### Materials and Method

Studies on this issue were carried out in experiments on healthy high-yielding black-motley cows of 3-4 lactations in 2 weeks after calving.

Estrus was diagnosed by visual inspection and according to the testimony of the "Cross-12" indicator (Tyapugin *et al.*, 2017).

58 animals were included in the first study from the 14th day after calving. Ultrasound scanning was performed twice a week between 15 and 70 days using an ultrasound scanner SSD-900 (Aloka, Tokyo, Japan) equipped with a 7.5-MHz linear rectal sensor. They identified follicles with diameter of  $\geq 6$  mm and their relative location. Ovulation and external functional activity manifestations of the corpus luteum were qualified on an increase in progesterone level  $> 1$  ng / ml in peripheral blood. Follicles with sizes  $> 20$  mm in diameter were qualified as follicular pathology. The dates and artificial insemination number of obtaining pregnancy and period duration were taken in account. Diagnosis of pregnancy was carried out from 60 days after the last artificial insemination in the absence of hunting.

The blood for the study was taken twice a week before the ultrasound diagnostics. Progesterone concentration in the blood was determined by the enzyme-linked immunosorbent assay (ELISA) method.

47 cows were included in the second study. The studies were performed on cows with no manifestation symptoms of ovarian cyclicity signs in the 1st hunt only. Follicular formation process confirming the functional cyclic activity of the ovaries was studied twice a week from the 12th ( $\pm 1$ ) day after calving and until the second ovulation manifested itself (using the first experiment method). In two subsequent studies, follicles with a diameter of  $\geq 17$  mm were qualified as potentially capable of later developing into a dominant follicle, persistent follicle, or transformed into a follicular cyst. The follicle with such signs was aspirated. If the same follicle didn't stop growing, it was aspirated reaching a size of  $\geq 20$  mm. Aspirations were performed under ultrasound scanner control combined with 18th size needle the guiding channel of which was connected to the suction device LOIP LS-301 (LOIP, RF). Cows were immobilized by intramuscular injection of 2 Xylazine 20 Inj. Additionally, epidural anesthesia was provided with 5 ml of lidocaine hydrochloride for relieve and relax the rectovaginal area (Marelli *et al.*, 2014).

Insulin, estradiol, and rostenedione and progesterone concentrations in the follicular fluid were determined by a highly sensitive ELISA method. Insulin and progesterone concentrations in the peripheral blood were determined by the ELISA method as well (Bo and Mapletoft, 2014).

The exact and reliable characterization of the aspirated follicle either it was a follicular cyst, a

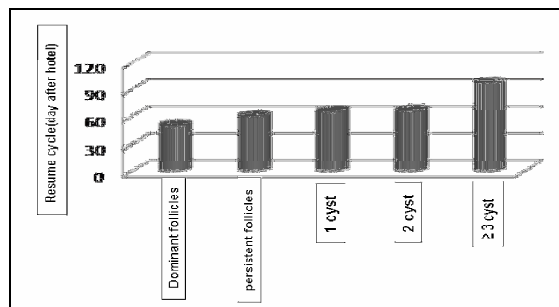
persistent or dominant follicle was not possible to determine. In this case, within research process of dominant persistent follicles and cysts are qualified on following characteristics: growth rate, which was determined by diameter increase from 10 mm to a maximum inversely proportional to the number of days of growth, size of the follicular formation diameter and ovarian activity.

An aspirated follicle is classified as a dominant if the follicle reaches a diameter  $\geq 20$  mm with a growth rate of  $<1$  mm per day with normal ovarian activity before and after aspiration. A persistent follicle was defined as a large follicle with a diameter of 17–21 mm and a growth rate of  $\leq 1$  mm per day, if at the same time it remained with the maximum size for the next two days. Follicular cysts were defined as large follicular structures with diameter 19–32 mm and increased daily growth rate of  $>1$  mm. It was assumed, ovulation didn't occur as a result of the refractory activity of the ovary before and/or after aspiration.

### Results and Discussion

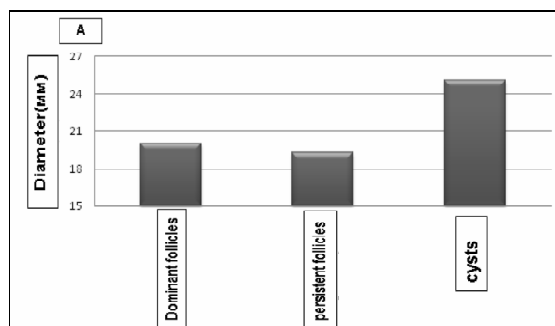
In the first part of the study of 58 cows, 52 of them (89.7%) showed 1, 2, 3 and 4 cycles after calving. The first ovulation for cows with cycle 1 occurred approximately at  $37.8 \pm 3.4$  days after calving, what was considered as delayed compared to the cows developing 2, 3 and 4 cycles. Their ovulation was recorded at  $27.1 \pm 1.6$ ;  $19.8 \pm 1.0$  and  $25 \pm 2.9$  days after calving, respectively. After completion of the last cycle the cows were inseminated. Service period duration was analyzed by pregnant cows, it was shorter for cows had previously developed 3-4 estrous cycles comparing to cows with fixing 1 and 2 cycles ( $84.2 \pm 5.02$ ;  $111.1 \pm 9.81$  days;  $P < 0.1$ ). 10.3% of cows didn't identified estrous cycle. Moreover, for these cows after normal growth to 16–20 mm the follicles were either subjected to atresia or transformed into cysts or persistent follicles. The ratio of cows number didn't showing the estrous cycle to the number of cows showing 1 or 2 cycles developing follicular pathologies was higher than the ration of cows showing more than 2 estrous cycles. We continued to monitor these cows in the second part of the research. Progesterone concentrations in the peripheral blood didn't differ in cows showing 1, 2 or 3 estrous cycles ( $0.5 \pm 0.1$  ng/ml) and had differences within  $0.2 \pm 0.1$  ng/ml with progesterone concentrations in the acyclic blood and in the range of  $1.4 \pm 0.5$  ng/ml in cows developed 4 estrous cycles. In the second part of the studies, the possibility of follicles persistence with possible transformation into follicular cysts was determined in 30% of 47 cows; 4 cows had dominant follicles; 4 of them had persistent follicles; 9 of them had follicular cysts. After aspiration of cysts, five cows developed 2-3

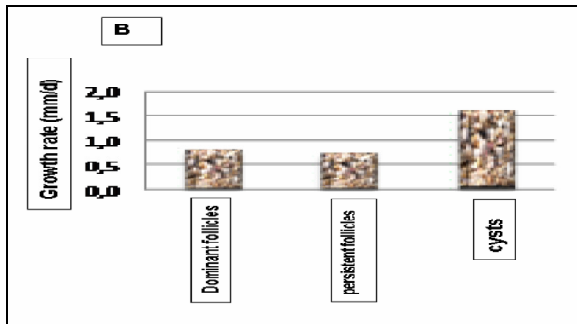
cysts again; 2 of these cows developed persistent follicles again. Cows developed more than 2 follicular cysts or persistent follicles were more likely observed by cows with delayed resumption of ovarian functional cyclicity ( $P < 0.05$ , Fig. 1)



**Fig. 1** : Ovarian cyclicity after calving. The resumption of functional cyclicity was determined by the presence of the day on which the second ovulation has occurred. The number of cows with  $\geq 3$  cysts, with a delayed cyclicity onset resumption in which  $\geq 3$  cysts were recorded has increased comparing with other groups.

For 17 cows 27 follicular ovarian structures were aspirated: 4 dominant follicles; 6 persistent follicles and 17 follicular cysts. The average diameter of the dominant, persistent follicles and follicular ovarian cysts was  $20.0 \pm 0.01$ ;  $19.0 \pm 0.6$  and  $25 \pm 0.9$  mm, respectively. The average cysts diameter of was significantly larger ( $P < 0.001$ ; Figure 2A) than dominant and persistent follicles diameter. Dominant and persistent follicles showed approximately the same growth rate ( $0.8 \pm 0.2$  and  $0.7 \pm 0.1$  mm/d, respectively), while cysts developed approximately 2 times faster ( $1.6 \pm 0.1$  mm/d;  $P < 0.002$ ; Figure 2B). Unique cysts (in cows that resumed ovarian cyclicity with ovulated formations after aspiration of intracystic contents) didn't differ in diameter and growth rate:  $n=4$ ;  $27.1 \pm 2.0$  mm a mm/d, respectively from first-formed cysts performance:  $n=5$ ;  $25.4 \pm 1.8$  mm and  $1.5 \pm 0.2$  mm/d, respectively, and the re-formed cysts:  $n=8$ ;  $24.1 \pm 1.3$  mm and  $1.6 \pm 0.2$  mm/d. With these ovario pathology performance cows were combined into a group ( $n=17$ ) for further research and obtained data analysis.





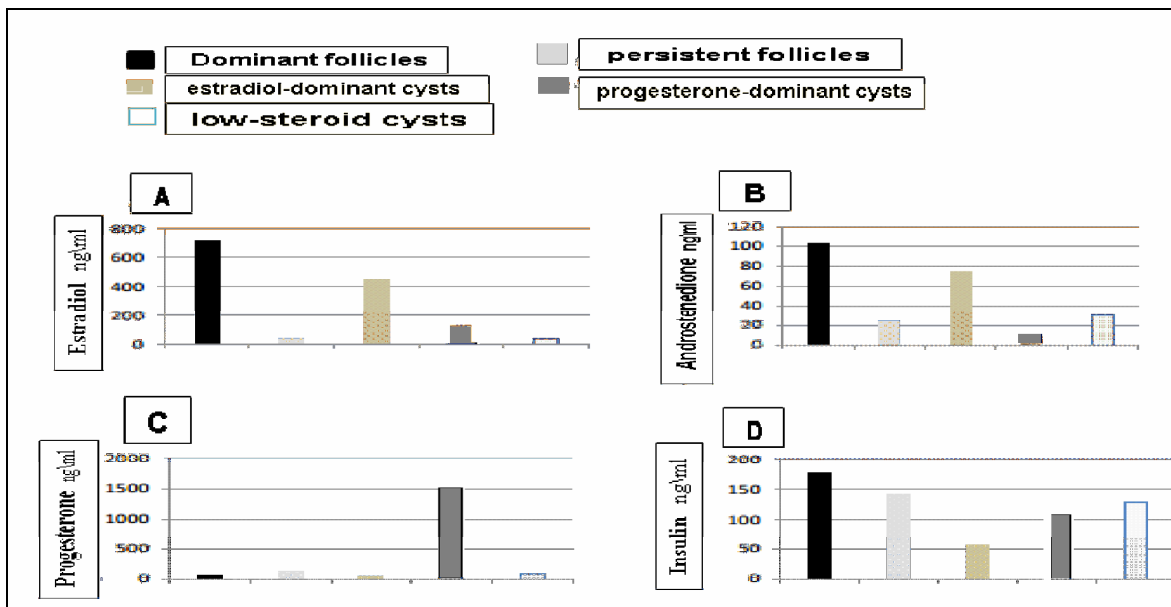
**Fig. 2 :** Development dynamics of dominant follicles, persistent follicles and ovarian cysts after calving: (A) Diameter during aspiration; and (B), Growth rate in diameter from 10 mm to a maximum diameter.

Follicular development growth of waves, resumed with the presence of a dominant formation and preovulatory follicle ovulation after aspiration of the dominant follicles of four cows. Three of these cows, (75%), with follicles defined as persistent and after their aspiration has shown a new cyclicity at once. At the same time, symptomatology suggested an anovulatory cycle in one cow, since after aspirating persistent formation, the new showed a normal growth rate till the reaching of 15-17 mm diameter. However, it hasn't ovulate, has decreased in size and disappeared with time. This trend was observed in this cow during the entire study period (from 12 to 79 days after calving).

Cows with isolated cysts (45%) periodically showed ovarian cycling and ovulation. However, other cows with cysts (55%), after aspiration, developed either cysts or persistent follicles. Two cows resumed ovarian cyclicity after secondary aspiration of the cyst. Three other cows developed further 3 or more follicular cysts. At the same time, we observed a correlation between the delay in cyclicity restoration ( $99.6 \pm 5.9$  days after delivery) with the formation of only a single cyst ( $n=1$ ) or one dominant or persistent follicle ( $67.3 \pm 8.2$ ;  $50.7 \pm 5$ , 7 and  $61 \pm 3.5$  days after delivery, respectively;  $P < 0.02$ ).

The classification of cysts into types was carried out taking into account hormones concentrations in the follicular fluid (Figure 3A-D). Cystic structures ( $n=17$ ) were characterized by a normal estradiol concentration or intracystic contents (284-659 ng/ml) and progesterone (20-113 ng/ml) in cystic fluid. Progesterone-dominant cysts ( $n=5$ ) were performed by an increase in progesterone concentration (586 - 3288 ng/ml) and a decrease in estradiol (0.06 - 330 ng/ml) in cystic.

Low-steroid cysts ( $n=5$ ) were performed by a low concentration of both estradiol (23-61 ng/ml) and progesterone (17-205 ng/ml) (Fig. 3A-D) in cystic fluid.



**Fig. 3 :** Hormones content in follicular fluid during ovaries functional formations (estradiol, progesterone, dominant cysts and low-steroid cysts). The sections show concentrations of (A) Estradiol, (B) Androstenedione, (C) Progesterone, and (D) Insulin.

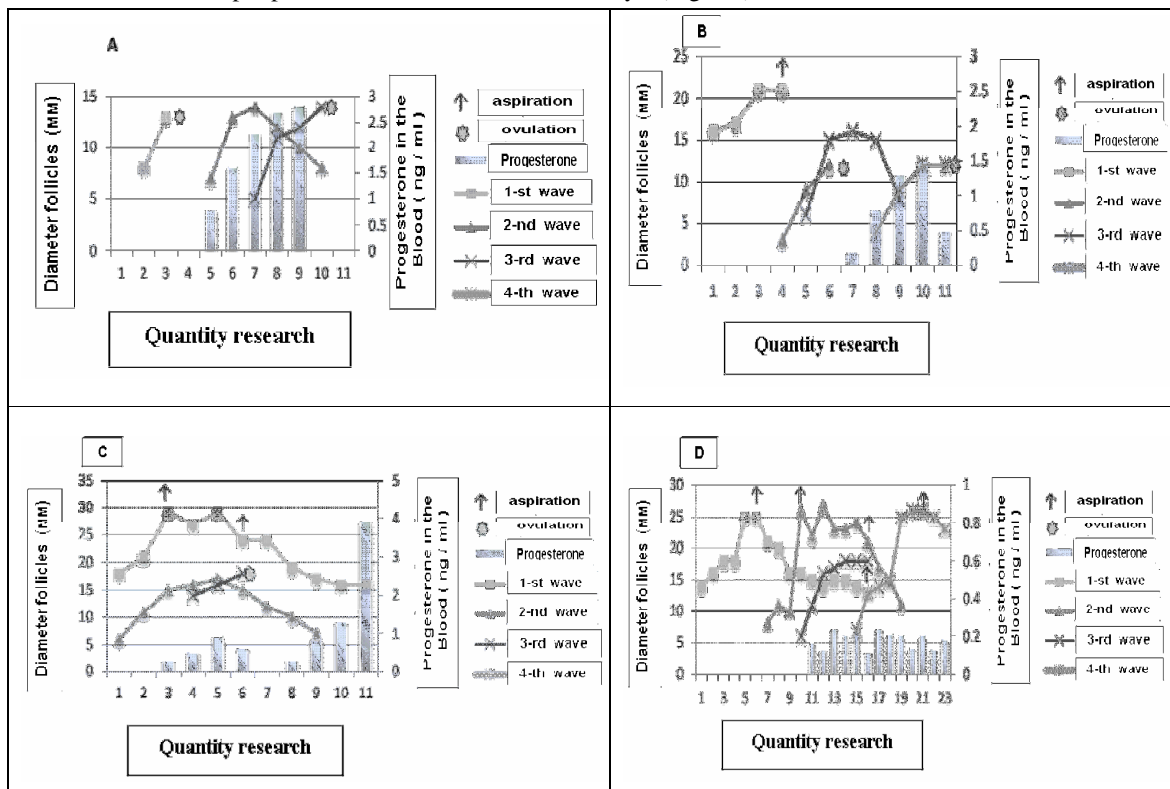
Average concentration of estradiol in progesterone-dominant contents and low-steroid cysts and persistent follicles ( $130 \pm 79$ ;  $37 \pm 7.3$  and  $43 \pm 49$  ng/ml, respectively) was lower than in dominant

follicles and estradiol-dominant cysts ( $713 \pm 140$  and  $449 \pm 53$  ng/ml, respectively,  $P < 0.001$  (Fig. 3A). High concentrations of estradiol in the follicular fluid of the dominant follicles were also estradiol-dominant cysts performance (Fig. 3A). Androstenedione concentrations in follicular fluid were higher in dominant follicles than in progesterone-dominant cysts ( $102 \pm 4.7$ ;  $7.3 \pm 1.7$ , respectively,  $P < 0.04$ , Fig. 3B). Androstenedione concentrations were slightly higher in the follicular fluid of the dominant follicles, compared with the persistent follicles ( $24.2 \pm 10.2$  ng/ml, Fig. 3B). The progesterone concentration in the follicular fluid of progesterone-dominant cysts was higher ( $1440 \pm 475$  ng/ml,  $P < 0.01$ ; Fig. 3 C) than in all other follicles and ranged from  $50 \pm 14$  ng/ml to  $138 \pm 57$  ng/ml in persistent follicles contents. Despite a slight difference in insulin concentration in follicular fluid in estradiol-dominant cysts, it was significantly lower than in the dominant follicles ( $57 \pm 28$  pg/ml and  $177 \pm 104$  pg/ml, respectively; Fig. 3D).

In the first week after calving progesterone concentrations in the peripheral blood were fixed, as a

rule, at the basal level. Increasing the level of progesterone ( $>1$  ng /ml) in isolated cases can be explained by the lysis retention of the corpus luteum structures that was confirmed by the results of ultrasonographic diagnostics (Fig. 4 A).

Low levels of progesterone concentrations were identified in peripheral blood in 4 of 5 cows that developed progesterone-dominant cysts in inactive corpus luteum presence. Average progesterone concentration in the follicular fluid in these cows was 1654 ng/ml, and only in one cow it was 586 ng/ml. At the same time, these values has corresponded to a low progesterone concentrations level in peripheral blood ( $0.32 \pm 0.09$  ng/ml) and what can explain ovulation absence in a certain number of cows. Progesterone concentration in the blood decreased to the basal values, which contributed to the ovulatory process (Figure 4C). One cow had a pronounced prolonged period of progesterone concentrations reduction to  $0.17 \pm 0.08$  ng/ml with a dominant follicle conjugate persistence that subsequently converted into an estradiol-dominant cyst (Fig. 4D).



**Fig 4 :** Follicular and cystic growth connection and progesterone concentration in peripheral blood. (A) normal follicular growth; (B) growth dynamics of a persistent follicle; (C) progesterone-dominant cyst formation, ovarian cyclicity is resumed after aspiration; (D) persistent estrogen-dominant cysts.

We experienced the main difficulty in research work on ovarian cysts problem due to the fact that

formation process and cysts presence in practice are only diagnosed retrospectively.

In this part of our research cyst diameter averaged  $25.2 \pm 2.36$  mm, while the persistent follicles basically reached 19.3 mm diameter. It should be noted that diameter size of the studied formation alone is not a reliable sign for the differential diagnosis of both follicular cysts and persistent follicles. However, this factor significantly complements other signs - the growth rate and functional activity nature of the ovary, which more reliably makes it possible for carrying out differential diagnostics. In this regard, we observed such a feature as a twofold increase in rate growth of the cysts diameter size (mm/d), in contrast to the uniform growth rate of dominant and persistent follicles diameter. This circumstance justifies expedient usage need for the differential diagnosis of ultrasound imaging research method directly in production conditions. Although the rates of persistent and dominant follicles development hasn't had significant differences, in both cases they made possible the prediction of the possibility for cyst formation relatively accurately, which is consistent with the other researchers findings (Cattaneo *et al.*, 2014).

Our previous studies have shown that a decrease of androstenedione level and  $17\beta$ -estradiol in the follicular fluid of persistent follicles performs their initial atresia stage. At the same time, in a cyst with a characteristic diameter, theca and granulosa thickness and hormone content in the follicular fluid indicate formation beginning of gonadotropic hormones receptors analogically with dominant follicles processes (Marelli *et al.*, 2014). Thus the primary dominant follicle development should be performed by the following features: growth rate ( $<1$  mm per day), static, when functional atresia precedes structural regression, while the follicular wave, on the contrary, is characterized by a decrease in the estradiol and inhibin secretion and new wave and follicle populations beginning while simultaneously inhibiting FSH increment by the pituitary body (Matiller *et al.*, 2014; Gabriel *et al.*, 2016).

Several researchers believe that persistent follicles are dominant follicles, in the prolonged resting stage, which contributes to functional (in the absence of morphological) atresia. This statement proves the results of ultrasonography. In our studies these circumstances were observed in the presence of low-steroid cysts (type 3) and to a lesser extent, in cases of cysts transformed from non-dominant follicles presence. Consequently, low-steroid cysts can form as primary pathological structures ( $n=2$ ) or initiate their new development after aspiration provoking so-called "follicular renewal" ( $n=3$ ). Low-steroid cysts aspiration led to the cystic formations renewal as in the cases of cysts transformed from non-dominant follicles, what is consistent with the

findings of other researchers (Ivanov and Gavrilov, 2015; Miura *et al.*, 2015; Yusupov and Shaev, 2013).

### Conclusions

It should be noticed that emergence and development mechanism of persistent follicles and ovarian cysts remains largely incomprehensible and this statement comply with the conclusions of other researchers (Marelli *et al.*, 2014). It is generally recognized that the disruption of the normal endocrine balance plays a major and initial role in the development of cysts. Hormonal imbalance during the postpartum period leads to impaired ovulation and follicular pathologies development (Kuzmich *et al.*, 2017). It was proved that in early puerperal period, about 25% of cows with cysts had a subluteal level of progesterone concentration in the peripheral blood which can be a trigger for persistent follicles formation with further transformation into follicular cysts. So a violation of positive feedback  $17\beta$ -estradiol-LH with negative changes in the progesterone concentration is likely to initiate a violation of ovulation and the formation of cysts in the early post calving period.

At the same time, the causes of the impaired positive feedback mechanism -  $17\beta$ -estradiol-LH remain unclear, however these are the reasons for persistent follicle formation and follicular cyst formation after calving. Low levels of progesterone concentration in the peripheral blood appear to be the main symptom and initial cause of follicles persistence of and cysts appearance. This obscure mechanism forming the basis for ovarian pathologies formation after calving determines the main perspective direction and current research strategy post-calving ovarian pathologies.

### References

- Anzorov, V.A. and Moryakina, S.V. (2017). The content of progesterone and estradiol- $17\beta$  in the blood of highly productive cows after the elimination of follicular cysts. *Digest:6th annual final conference of the teaching staff of Chechen State University* - 65-69.
- Bisinotto, R.S.; Ribeiro, E.S. and PSantos, J.E. (2014). Synchronisation of ovulation for management of reproduction in dairy cows. *Supplement s1 (New Science- New Practices International Cow Fertility Conference 18-21 May 2014, Westport, Ireland)*, 8: 151-159.
- Gabriel, A. Bó.; JoséJavier, de la Mata; Pietro, S.B. and Alejo, M. (2016). Alternative programs for synchronizing and resynchronizing ovulation in beef cattle. *Theriogenology*, 86(1): 388-396.
- Bo, G.A. and Mapletoft, R.J. (2014). Historical perspectives and recent research on superovulation in cattle. *Theriogenology*, 81(1): 38-48.

- Cattaneo, L.; Signorini, M.L.; Bertoli, J.; Bartolomé, J.A.; Gareis, N.C.; Díaz, P.U.; Bó, G.A. and Ortega, H.H. (2014). Epidemiological Description of Cystic Ovarian Disease in Argentine Dairy Herds: Risk Factors and Effects on the Reproductive Performance of Lactating Cows. *Reproduction in Domestic Animals*, 49(6) : 1028-1033.
- Dias, F.C.; Khan, M.I.; Sirard, M.A.; Adams, G.P. and Singh, J. (2013). Differential gene expression of granulosa cells after ovarian superstimulation in beef cattle. *Reproduction*, 146(2): 181- 191.
- Eborn, D.R.; Cushman, R.A. and Echternkamp, S.E. (2013). Effect of post weaning diet on ovarian development and fertility in replacement beef heifers. *Journal of Animal Science*, 91(9) :4168 - 4179.
- Garcia, G.A.; Tribulo, A.; Yapura, J.; Adams, G.P.; Singh, J. and Mapletoft, R.J. (2015). Lengthened superstimulatory treatment in cattle: evidence for rescue of follicles within a wave rather than continuous recruitment of new follicles. *Theriogenology*, 84(3) :467-76.
- Grigorieva, I.E.; Kondruchina, S.G. and Trifonov, L.A. (2014). Influence of persistent corpus luteum in cows on fertility and metabolism. *Journal of Agrarian Science of Euro-Northeast*, 38(1) :45- 48.
- Ivanov, D.V. and B.V. Gavrilov (2015). Comparative evaluation of the therapeutic efficacy of follicular cysts treatment in cattle in the digest. *scientific support of the agro-industrial complex. Digest of articles based on the materials of the 71st Scientific and Practical Conference of Students on the basis of research. Ministry of Agriculture of the Russian Federation; FSBEI of HE "Kuban State Agrarian University named after I.T. Trubilina. - 2016.* 88-92.
- Ivanov, D.V. and Gavrilov, B.V. (2016). Causes of follicular cysts in cows and a comparative evaluation of treatment methods. *Collection: Bulletin of scientific and technical creativity of youth of the Kuban State Agrarian University. In 4 parts. Compiled by A. Ya. Barchukova, Ya. K. Tosunov; Edited by A. I. Trubilin, resp. ed. A. G. Koshchaev*, 134 -137.
- Jaskowski, J.M.; Jlechnowicz, J. and Nowak, W. (2006). Nectore przyczyny obniżającej się płodności u krow mlecznych. *Medycyna Wetejnaryja*, 62(4): 385-389.
- Kaplunov, V.R. and Gavrichenko, N.I. (2017). Peculiarities of folliculogenesis in cows with different types of stress resistance. *Actual problems of intensive development of animal husbandry*, 20(2) : 319-325.
- Kuzmich, R.G.; Rybakov, Y.A.; Yatsyna, V.V.; Khodykin, D.S. and Makarenko, N.N. (2017). The functional state of the reproductive system in cows with postpartum anestrus. *Scientific notes of the educational institution of the Vitebsk order. Badge of Honor State Academy of Veterinary Medicine*, 53(2): 48-51.
- Lopez, H.; Whittaker, P.; Behrouzia, A.; Mapletoft, R.J. and Colazoa, M.G. (2018). Effect of initial GnRH and time of insemination on reproductive performance in cyclic and acyclic beef heifers subjected to a 5-d Co-synch plus progesterone protocol. *Theriogenology*, 106: 39-45.
- Marelli, B.E.; Díaz, P.U.; Salvetti, N.R.; Rey, F. and Ortega, H.H. (2014). mRNA expression pattern of gonadotropin receptors in bovine follicular cysts. *Reproductive Biology*, 14(4): 276-281.
- Matiller, V.; Stangaferro, M.L.; Díaz, P.U.; Ortega, H.H.; Rey, F.; Huber, E. and Salvetti, N.R. (2014). Altered expression of transforming growth factor- $\beta$  isoforms in bovine cystic ovarian disease. *Reproduction in Domestic Animals*, 49(5): 813-823.
- Miura, R.; Haneda, S.; Kayano, M. and Matsui, M. (2015). Short communication: Development of the first follicular wave dominant follicle on the ovary ipsilateral to the corpus luteum is associated with decreased conception rate in dairy cattle. *Journal of Dairy Science*, 98(1): 318-321.
- Pancarci, S.; Jordan, E. and Risco, C. (2008). Use of estradiol cypionate in a presynchronized timed artificial insemination program for lactating dairy cattle. *J. Dairy Sci.*, 85 : 122-131.
- Ribeiro, E.S.; Galvao, K.N.; Thatcher, W.W. and Santos, J.E.P. (2012). Economic aspects of applying reproductive technologies to dairy herds. *Anim Reprod*, 9(3): 370-387.
- Tyapugin, E.A.; Simonov, G.A.; Pankratova, A.V. and Niu, V. (2017). Determination of the time of insemination of cows based on the indication of hunting by instrumental methods. *Dairy and Beef Cattle Breeding*, 6: 33-35.
- Wijma, R.; Stangaferro, M.L. and Giordano, J.O. (2016). Circulating progesterone dynamics after intravaginal instillation of prostaglandin-F $_{2\alpha}$  to lactating dairy cows. *Theriogenology*, 85(9) : 1660-1668.
- Wiltbank, M.C.; Souza, A.H.; Carvalho, P.D.; Cunha, A.P.; Giordano, J.O.; Fricke, P.M.; Baez, G.M. and Diskin, M.G. (2014). Physiological and practical effects of progesterone on reproduction in dairy cattle. *Supplement s1(New Science-New Practices International Cow Fertility Conference 18-21 May 2014, Westport, Ireland)*, 8: 70-81.
- Yusupov, S.P. and Shaev, R.K. (2013). Results of treatment of cows with follicular ovarian cysts. *Scientific notes of the Kazan State Academy of Veterinary Medicine named after N.E. Bauman*, 216 :412-415.
- Zhazhgaliyeva, A.T.; Avdeenko, V.S. and Kozyrev, S.G. (2014). Endocrine mechanisms of folliculogenesis regulation in beef cattle. *Reports of Gorsky State Agrarian University*, 51(3): 147-150.