



# THE PROTECTIVE ROLE OF TAURINE AND *ZINGIBER OFFICINALE* ON ALUMINUM CHLORIDE INDUCED TESTICULAR INJURY AND IMPAIRED SPERMATOGENESIS IN ADULTS MALE RABBITS: BIOCHEMICAL, HORMONAL AND HISTOPATHOLOGICAL STUDY

**Bassim Khamess Kuoti Al-Rekabi**

Department of Animal Production, College of Agriculture, University of Sumer, 64005, Rifai Dhi Qar, Iraq.  
E-mail: kh\_bassim@yahoo.com

## Abstract

This study was designed to evaluate the protective effect of Taurine and *Zingiber officinale* on aluminum chloride ( $\text{AlCl}_3$ ) induced testicular damage and impaired spermatogenesis in adults male rabbits. Thirty adult male rabbits 1.5 -1.80 kg, 22-24 weeks old were used in this study. The animals were randomly and equally divided into five equal groups, 6 animals per each: Control group (Control negative): received distilled water orally 5 ml/kg/day for 21 days. First treated group (Control positive T1): received  $\text{AlCl}_3$  20 mg/kg/day (I.P) as a single dose for 21 days. Second treated group (T2): received  $\text{AlCl}_3$  20 mg/kg/day (I.P) and after 1 hour later received Taurine orally 200 mg/kg/day for 21 days. Third treated group (T3): received  $\text{AlCl}_3$  20 mg/kg/day (I.P) and after 1 hour later received *Zingiber officinale* orally 200 mg/kg/day for 21 days. Fourth treated group (T4): received  $\text{AlCl}_3$  20 mg/kg/day I.P and after 1 hour later received a combination of half a dose of Taurine 100 mg/kg/day and *Zingiber officinale* 100 mg/kg/day for 21 days. The blood samples were taken after 21 days of treatment to evaluate biochemical parameters includes reduced glutathione (GSH), superoxide dismutase (SOD), catalase (CAT), and malondialdehyde (MDA). Reproductive hormone FSH, LH, Testosterone and liver function enzymes AST, ALT and ALP were also evaluated. The histopathological examination of testis and epididymis were done. The obtained results demonstrate that male rabbits treated with  $\text{AlCl}_3$  revealed a significant ( $P < 0.05$ ) increase in serum levels of MDA, AST, ALT and ALP, significant ( $P < 0.05$ ) decrease in GSH, SOD, CAT, FSH, LH, and Testosterone. The histopathological study revealed that  $\text{AlCl}_3$  caused severe degeneration of spermatogenic stage and complete loss of spermatozoa in the tubule of epididymis. In contrast, Taurine or *Zingiber officinale* and their combination caused a significant ( $P < 0.05$ ) decrease in MDA, AST, ALT and ALP, significant ( $P < 0.05$ ) increase in GSH, SOD, CAT, FSH, LH, and Testosterone with normal spermatogenesis stage and epididymal tubules filled with spermatozoa. It has been concluded from the present study that combination of Taurine and *Zingiber officinale* appeared the best protective effect against testicular and epididymal damage induced by  $\text{AlCl}_3$  better than each drug alone through improving antioxidant enzyme activities in  $\text{AlCl}_3$  treated group leading to declined MDA level and reduced lipid peroxidation.

**Key words :** Taurine, *Zingiber officinale*,  $\text{AlCl}_3$ , testicular Injury, male rabbits.

## Introduction

Aluminum (Al) is the most abundant metal in the environment, comprise about 8% of the earth's crust (1). It is widely distributed and used in the manufacture of cosmetics, cookware, utensils, food additives, toothpaste, and found in mixture with oxygen, silicon, fluorine and other elements in the soil, rocks, clay and gems (2). It is also used in medicines and added to the drinking water for purification purposes (3). Aluminum enters into the

body from environment and from diet, mainly corn, yellow cheese, salts, herbs, spices, tea, and cosmetics such as antiperspirant and deodorant preparation and most of this aluminum is quickly removed by the kidneys which leading to renal dysfunction (4).  $\text{AlCl}_3$  induced reproductive toxicity and adverse effect on steroidogenesis (5). The major well-known toxicological properties of aluminum included microcytic hypochromic anemia (6), neurodegenerative disorders such as Alzheimer disease, amyotrophic lateral sclerosis and dialysis encephalopathy

(7), hepatotoxicity (8), genotoxicity (9), and toxicity both male reproductive system (10) and female ovaries (11). The toxic effects associated with aluminum are due to generation of reactive oxygen species (ROS) (12) and DNA oxidative deterioration (13). In the medicine field, Al complexes are now commonly used in the composition of many pharmaceutical conditions such as antacids, phosphate binders, toothpaste, aspirins, vaccines and antiperspirant. Furthermore, purification principles of water and food additives making them a potential threat (14). At the present time, the importance for utilize of herbal remedies in place of chemical drugs is increasing due to lesser side effects and their actions (15). In fact, a number of herbs have defensive effect against cell oxidative stress (16). Furthermore, *Zingiber officinale* is one of the medicinal plant which is regarding as a safe herbal medicine and usually used as a food spice and as natural additive. It is a physically powerful antioxidant agent may reduced generation of free radicals (17). The antioxidant properties of *Zingiber officinale* was attributed to its major ingredients namely zingerone, gingerols, gingerdiol, shogaols and zingiberene (18). The major pharmacological action comprised immunomodulatory, anti-tumorigenic, anti-inflammatory, anti-apoptotic, anti-hyperglycemic, anti-lipidemic and antiemetic action (19). In general, it is companied a potent anti-oxidant and anti-inflammatory actions and revealed a significant anti-carcinogenic and anti-mutaginc activities (20). Also, anti-platelet, anti-emetic, anti-diabetic, anti-hypercholesterolaemia, anti-pyretic, anti-proliferation, and anti-toxic agent (21 and 22). Taurine (2-aminoethylsulphonic acid) is one of non essential, non protein sulphur-containing amino acids in most mammal tissues, which does not participate to protein synthesis, it is inert molecule without any reactive groups (23). It is synthesized either exogenously via dietary supply such as poultry, beef, pork, seafood, and developed meats or endogenously via biosynthesis from amino acids methionine and cysteine precursor. Furthermore, it is found in high concentrations in the heart, muscles, brain, liver, kidney, pancreas, spleen, small intestine, lungs, male and female reproductive organs and eyes of mammals, and also in sea food (24). It is a powerful antioxidant (25), anti-inflammatory and immune modulation (26) and anti-apoptotic (27), improve mitochondrial dysfunction by stabilized the mitochondrial electron transport chain and inhibiting ROS generation (28), anti-hyperglycemia and anti-lipidemia (29), anti-carcinogenic (30), anti-mutaginc properties (31), anti-proliferation (32), antidiabetic (33). It has been known that taurine can be synthesized by male reproductive organs (34). It has been restricted to

testicular leydig cells, testosterone in male, and peritubular cells surrounding seminiferous tubules. Moreover, it has been identified in humans testes and recognized as the most important free amino acid of sperm cells and seminal fluid (35).

## Materials and Methods

### Ethanolic extract of *Zingiber officinale* rhizomes

The fresh rhizomes of *Zingiber officinale* were obtained from the local market in Thi-Qar provenance / Iraq, plant material was identified at college of science / university of Thi-Qar. The plant material was washed with distilled water and then dried at room temperature for two days under shadow. The dried rhizome were cut into small pieces and ground into powder by using electric grinder for 3 minutes, 50 g of powder were put in round bottle flask, 200 ml of ethanol (70%) were added to flask and extracted for 12 hrs at 70°C. The extract was filtered by using white filter paper, then the extract were put in petridish and left at room temperature under shadow. The resulting was viscous substance with brown color, collection extracts were kept in stretched closed container and stored at 4°C until using according to (36).

### Chemical

The *Zingiber officinale* extract were dissolved in distilled water and administrated orally as single doses daily. Taurine, Kosher  $\geq 98\%$  obtained from (Sigma, Aldrich, Switzerland), CAS No.107-35-7, EC No.203-483-8, MDL No. MFCD 00008197 were dissolved in distilled water (62.5 mg/ml at 20 °C), water (65 mg/ml at 12°C) and DMSO ( $<1$  mg/ml at 25 °C) and administrated orally as single doses daily. Aluminum chloride anhydrous powder ( $\text{AlCl}_3$ ), 99.999%, CAS No.7446-70-0, EC No.231-208-1, MDL No.MF.CD 00003422 were obtained from (Sigma, Aldrich St. Louis, MO, USA) 2 gram of  $\text{AlCl}_3$  was dissolved in 100 ml distilled water to prepare a stock solution (20 mg/ml) and was administrated orally. The working stock solutions was prepared weekly and kept in a plane bottle at 4°C.

### Experimental animals

A total of thirty adult male rabbits (*Lepus cuniculus*) with body weight ranged 1.5-1.80 kg, 22-24 weeks were brought from the local markets in Basrah province. Rabbits were kept for an adaptation period for 1 month in animal house of College of Veterinary Medicine/ University of Basrah. The experimental animals were kept in individual cages, provided with pellet foods and tap water ad libitum. The animals were given anticoccidiosis drug (Amprolium) at a dose of 0.5 ml/L and ivermectin at a dose of 0.1 mg/rabbit for control of

internal and external parasites through drinking water daily for 2 weeks. These animals are maintained in air-conditioned quarters 24°C under standard husbandry condition with alternate 12 hours light /dark by use of two fluorescent lamps, and humidity rate was about 50%.

### Experimental design

After acclimatization period, animals were randomly and equally divided into five equal groups, 6 animals per each: Control group (Control negative): received distilled water orally 5 ml/kg/day for 21 days. First treated group (Control positive T1): received  $\text{AlCl}_3$  20 mg/kg/day orally as a single dose for 21 days. Second treated group (T2): received  $\text{AlCl}_3$  20 mg/kg/day orally and after 1 hour later received Taurine orally 200 mg/kg/day for 21 days. Third treated group (T3): received  $\text{AlCl}_3$  20 mg/kg/day orally and after 1 hour later received *Zingiber officinale* orally 200 mg/kg/day for 21 days. Fourth treated group (T4): received  $\text{AlCl}_3$  20 mg/kg/day orally and after 1 hour later received a combination of half a dose of Taurine 100 mg/kg/day and *Zingiber officinale* 100 mg/kg/day orally for 21 days.

### Blood samples collection

Each male rabbits before sacrifice were first weighed and then anaesthetized by placing them in a closed beaker containing cotton sucked with chloroform for anesthesia. The abdominal cavity was opened up through a midline abdominal incision to take samples. About 5ml fasting blood were obtained by cardiac puncture. Samples were allowed to clot, then all samples were separated by centrifuge at 300 rpm for 10 minutes to obtained serum samples immediately for detection MDA levels, and the rest serum was stored at -20°C until using for other biochemical and hormonal studies. The serum samples separated into many Eppendorf tubes to avoid repeated thawing. All tubes were stored at (-4c) until they were analyzed.

### Estimation of reproductive hormones

Testosterone, follicular stimulating hormone (FSH), and luteinizing hormone (LH) were analyzed by using ELISA kit manufactured by human diagnostic company, Germany. Measure absorbance of all wells at 450 nm and record absorbance values for each standard and sample. calculate the mean absorbance values of all duplicates.

### Estimation of AST, ALT and ALP

The activity of serum transaminases activity AST or ALT is determined by using a special kit obtained from BIOMÉRIEUX ® SA Transaminases-Kit, France according to method described by (37) and its absorbance

can be measured at 505 nm wave length. The serum activity of ALP is determined according to method of (38) by using a special kit obtained from Giesse, Italy, and its absorbance can be measured at 405 nm wave length.

### Estimation of lipid peroxidation and oxidative stress biomarker

#### Evaluation of serum malondialdehyde (MDA)

The principle was based on spectrophotometric assessment. The thiobarbituric acid (TBA) obtained from Fluka® analytical (Sigma-Aldrich) reacts with MDA to form thiobarbituric acid reactive substance (TBARS). The absorbance of the resultant pink product measured at 535nm.

#### Reagent preparation and procedure

Trichloroacetic acid (TCA) 75 ml of 20% obtained from (Hopkin and Williams Company, Germany). 2 ml of concentrated hydrochloric acid HCl (37%) obtained from (Fisher Scientific chemical, UK). 0.375gm of thiobarbituric acid (TBA) obtained from Fluka® analytical (Sigma-Aldrich). All these substances were mixed and the final volume was completed to 100 ml D.W to form TCA-TBA-HCl reagent. 1ml of serum was combined with 2 ml of TCA-TBA-HCl solution and mixed carefully, after that boiled for 15 minutes in water bath. After cooling, precipitate was removed by centrifugation at 3000 rpm for 10 minutes. The absorbance of solution was determined at 535nm wave length against reagent blank which was containing all the reagent minus serum, the sample were measured spectrophotometrically.

**Calculation of MDA values:**  $[\text{MDA } (\mu\text{mol} / \text{L}) = \text{A1} - \text{A0} / 1.56 \times 10]$

#### Evaluation of antioxidant enzymes activities (GSH, SOD and CAT)

The activity of GSH was measured according to method described by (39). This method based on the reduction of 5,5 dithiobis (2-nitrobenzoic acid - DTNB) obtained from (Fluka® analytical, sigma-Aldrich) with glutathione (GSH) to product a yellow compound. The reduced chromogen is directly relative to GSH concentration and its absorbance can be measured at 412 nm wave length. The serum superoxide dismutase (SOD) activity was determined according to a modified photochemical nitroblue tetrazolium (NBT) method obtained from(Sigma-Aldrich, St. Louis, MO, USA) utilizing sodium cyanide as peroxidase inhibitor and its absorbance can be measured at 560 nm wave length before and after lighting (40). Furthermore, serum catalase (CAT) activity was measured by the decrease

**Table 1 :** The effect of aluminum chloride (AlCl<sub>3</sub>) and the ameliorating role of Taurine, *Zingiber officinale* and their combination on antioxidant enzymes activities (GSH, SOD, CAT) and malondialdehyde (MDA) of adult male rabbits. Mean± SD.

Parameters	MDA (µmol/L)	GSH (µmol/L)	SOD (IU/ml)	CAT (IU/ml)
Control 5 ml/kg D.W Control -ve	0.50±0.02a	8.46±0.27b	7.13±0.12b	62.24±2.65b
AlCl <sub>3</sub> 20 mg/kg/day Control +ve T1	3.23±0.24c	3.63±0.16a	3.50±0.23a	27.30±0.15a
AlCl <sub>3</sub> 20 mg/kg/day+Taurine 200 mg/kg/day orally T2	1.23±0.02b	6.67±0.04b	5.35±0.32b	48.83±1.83b
AlCl <sub>3</sub> 20 mg/kg/day + <i>Zingiber officinale</i> 200 mg/kg/day orally T3	1.22±0.02b	6.69±0.12b	5.38±0.03b	50.32±4.87b
AlCl <sub>3</sub> 20 mg/kg/day + Combination of Taurine 100 mg/kg + <i>Zingiber officinale</i> 100 mg/kg T4	0.52±0.05b	9.38±0.34b	7.38±0.38b	65.33±2.04b
LSD	0.7	1.77	1.75	11.92

**Table 2 :** The effect of aluminum chloride (AlCl<sub>3</sub>) and the ameliorating role of Taurine, *Zingiber officinale* and their combination on some male reproductive hormones (FSH, LH, testosterone) of adult male rabbits. Mean± SD.

Parameters	FSH ng/ml	LH ng/ml	Testosterone ng/ml
Control 5 ml/kg D.W Control -ve	7.21±1.18a	2.10±0.23a	3.83±0.03 a
AlCl <sub>3</sub> 20 mg/kg/day Control +ve T1	2.85±0.54b	0.45±0.38b	0.57±0.02 b
AlCl <sub>3</sub> 20 mg/kg/day + Taurine 200 mg/kg/day orally T2	4.16±1.03a	2.36±0.42a	2.80±0.02 a
AlCl <sub>3</sub> 20 mg/kg/day + <i>Zingiber officinale</i> 200 mg/kg/day orally T3	4.18±1.06a	2.35±0.40a	2.78±0.02 a
AlCl <sub>3</sub> 20 mg/kg/day + Combination of Taurine 100 mg/kg + <i>Zingiber officinale</i> 100 mg/kg T4	8.30±1.39a	3.69±0.38a	4.20±0.06 a
LSD	1.31	1.65	2.21

Small letters means significant differences between treatment at (P≤0.05).

**Table 3 :** The effect of aluminum chloride (AlCl<sub>3</sub>) and the ameliorating role of Taurine, *Zingiber officinale* and their combination on liver function enzymes AST, ALT, and ALP of adult male rabbits. Mean± SD.

Parameter	AST(U/L)	ALT(U/L)	ALP(U/L)
Control 5 ml/kg D.W Control -ve	6.74±0.80 a	8.72±0.82a	5.68±0.42a
AlCl <sub>3</sub> 20 mg/kg/day Control +ve T1	34.78±3.25c	30.33±2.10b	24.22±3.30b
AlCl <sub>3</sub> 20 mg/kg/day + Taurine 200 mg/kg/day orally T2	13.36±1.16 b	12.92±0.64a	12.57±0.43 a
AlCl <sub>3</sub> 20 mg/kg/day + <i>Zingiber officinale</i> 200 mg/kg/day orally T3	13.20±0.81b	12.86±0.61a	12.40±0.65 a
AlCl <sub>3</sub> 20 mg/kg/day + Combination of Taurine 100 mg/kg + <i>Zingiber officinale</i> 100 mg/kg T4	9.68±0.74a	8.32±1.04a	8.21±0.48 a
LSD	3.52	17.41	11.65

Small letters means significant differences between treatment at ( P≤0.05).

in absorbance due to H<sub>2</sub>O<sub>2</sub> consumption ( £ = 0.04 mmol<sup>-1</sup> cm<sup>-1</sup>) according to Mueller and Riedel (1997) (41).

### Histopathological examination

Testes and epididymis were collected from all groups and prepared for histopathological study according to method described by (42) and fixated in Bouin's fluid for

24 hours and transferred into 10% formalin. They were washed with water to remove the fixative to avoid the interaction between the fixative and staining materials used later. Water had been completely extracted from fragments by bathing them successively in a graded series of ethanol and water. Bathing the dehydrated fragments

in solvent xylene for 30 - 60 minutes, this step was repeated 3 times. As tissues were cleared, they generally became transparent. Infiltrated and embedded in melted paraffin in an oven, typically at 52-60°C. The heat causes solvent to evaporate, and space within tissues become filled with paraffin. After hold from oven, specimen let at room temperature to be solid and removed from their containers in order to sectioning. They were put in the rotary microtome and were sliced by microtome, steel blade into sections 5 micrometers thick, then sections were floated on water bath (50-55°C) and then transferred into glass slides coated with Mayers albumin as adhesive agent and left to dry. The histological section of testes and epididymis were stained with Hematoxylin-Eosin stain and microscopically analyzed.

### Statistical analysis

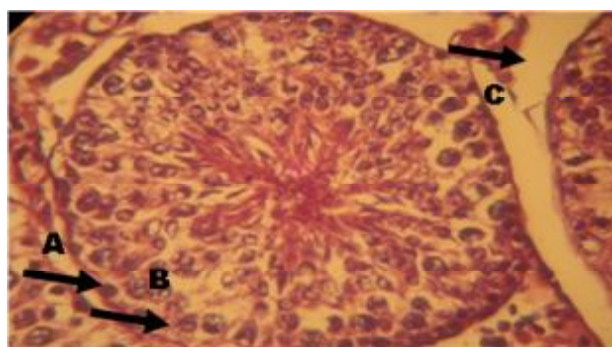
In this study, one way ANOVA analysis and LSD tests are used according to Statistical Package for Social Sciences (SPSS, version 13) program. The data were expressed as Mean  $\pm$  standard deviation (Mean  $\pm$  SD). Least significant difference test (LSD) was used to test the difference between groups;  $P < 0.05$  was considered significant (SPSS, 2001).

### Results

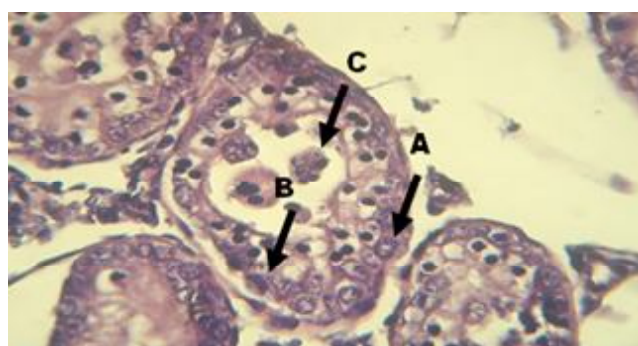
The obtained results indicate that male rabbits treated with aluminum chloride ( $AlCl_3$ ) revealed a significant ( $P < 0.05$ ) increase in MDA value, AST, ALT and ALP, significant ( $P < 0.05$ ) decrease in GSH, SOD, CAT, FSH, LH and Testosterone compared to control group. The histopathological study revealed that  $AlCl_3$  caused severe degeneration of spermatogenic stage and complete loss of spermatozoa in epididymal tubules. While, groups of animals treated with Taurine or *Zingiber officinale* and their combination caused a significant ( $P < 0.05$ ) decrease in MDA value, AST, ALT and ALP, significant ( $P < 0.05$ ) increase in GSH, SOD, CAT, FSH, LH, and Testosterone with normal spermatogenesis stages and epididymal tubules filled with spermatozoa compared to groups that treated with  $AlCl_3$ . Furthermore, it was indicated that combination of Taurine and *Zingiber officinale* caused a highly significant decrease in MDA value, AST, ALT and ALP, a highly significant increase in GSH, SOD, CAT, FSH, LH and Testosterone and almost return to its normal levels compared with control value. Normal primary and secondary spermatocytes and spermatogenesis, with epididymal tubules filled with spermatozoa.

### Histopathological examination of testis

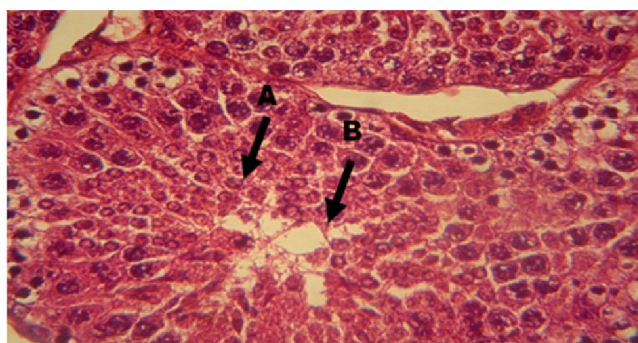
The results in fig. 2 indicate the male rabbits that received  $AlCl_3$  dose 20 mg/kg caused severe degeneration



**Fig. 1 :** Testis of normal male rabbit received 5ml/kg/day D.W as a control negative (H&E Stain, 400 X) revealed normal seminiferous tubule with complete stages of spermatogenesis, spermatogonia (A), sertoli cell (B) and leydig cell (C).

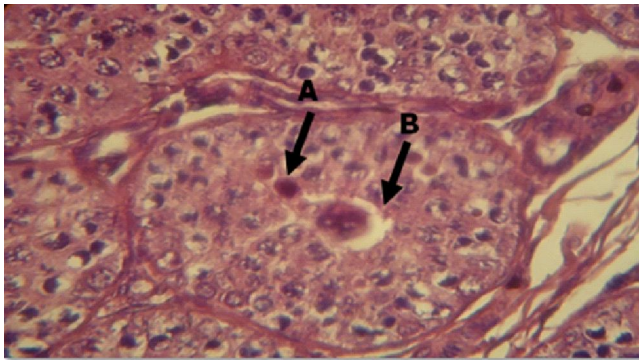


**Fig. 2 :** Testis of male rabbit received 20mg/kg/day  $AlCl_3$  as a control positive (H & F Stain, 400 X) revealed severe degeneration in spermatogenic stages with only sertoli cell (B), spermatogonia (A) and spermatid giant cells (C).

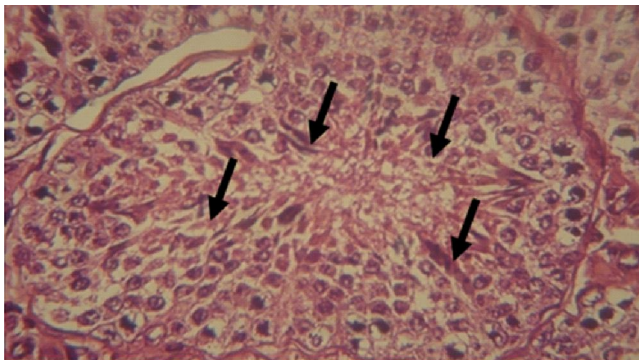


**Fig. 3 :** Testis of male rabbit received  $AlCl_3$  20mg/kg/day + Taurine 200 mg/kg/day (H & F Stain, 400 X) revealed primary and secondary spermatocytes (A), presence of few spermatozoa (B).

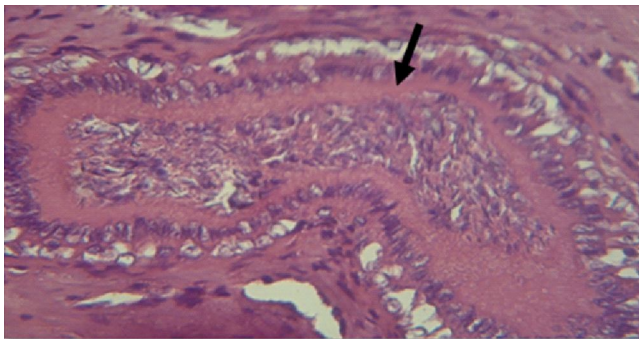
of spermatogenic stages represented by present only sertoli cell with few spermatogonia and spermatid giant cells after 21 days of exposure compared to control group (fig. 1). While, the male rabbits that treated with Taurine or *Zingiber officinale* revealed primary and secondary spermatocytes with few spermatozoa in lumen of seminiferous tubules compared to groups treated with



**Fig. 4 :** Testis of male rabbit received  $\text{AlCl}_3$  20mg/kg/day + *Zingiber officinale* 200 mg/kg/day (H & E Stain, 400 X) revealed primary and secondary spermatocytes (A), presence of spermatid giant cells (B).



**Fig. 5 :** Testis of male rabbit received  $\text{AlCl}_3$  20mg/kg/day + combination of Taurine 100 mg/kg/day and *Zingiber officinale* 100 mg/kg/day (H & E Stain, 400 X) revealed primary and secondary spermatocytes.

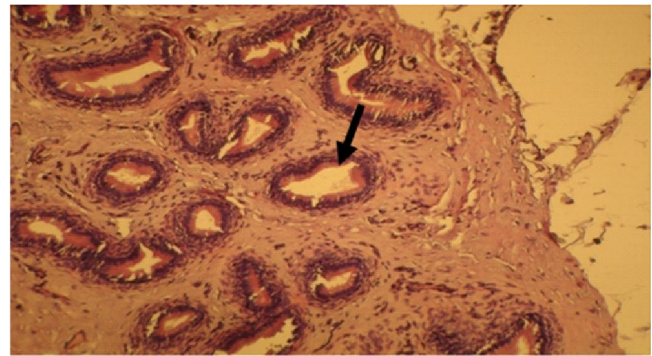


**Fig. 6 :** Epididymis of normal male rabbit received 5ml/kg/day D. W. as a control negative (H & E Stain, 400 x) revealed epididymal tubules filled with spermatozoa.

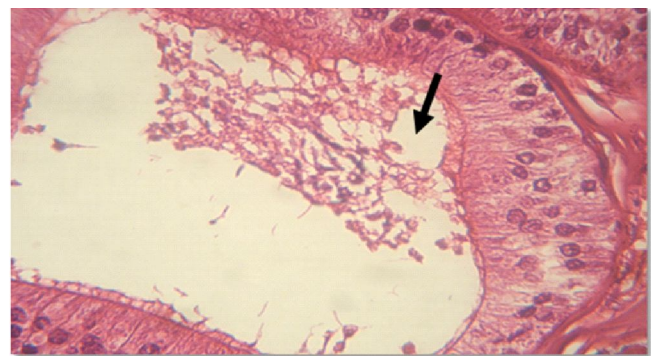
$\text{AlCl}_3$  (Figs. 3 and 4) respectively. It is also observe from figure (5) that combination of Taurine and *Zingiber officinale* give the best results with normal spermatogenic stages, normal primary and secondary spermatocytes compared to control and other treated groups.

#### Histopathological examination of epididymis

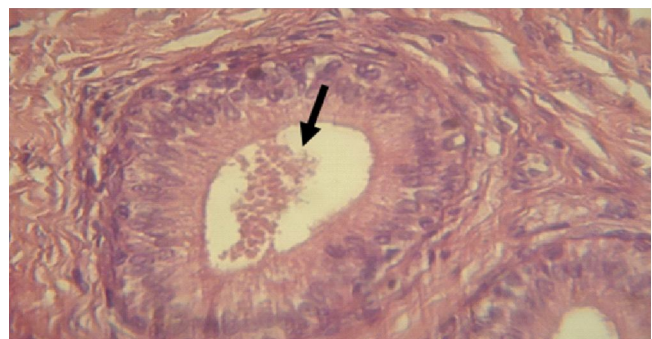
The results in Fig. 7 indicate the male rabbits that received  $\text{AlCl}_3$  dose 20 mg/kg revealed complete loss of



**Fig. 7 :** Epididymis of male rabbit received 20mg/kg/day  $\text{AlCl}_3$  as a control negative (H & E Stain, 400 x) revealed complete loss of spermatozoa in the tubule of epididymis.

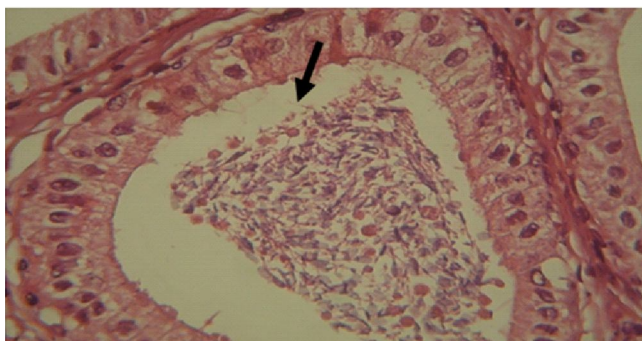


**Fig. 8 :** Epididymis of male rabbit received 20mg/kg/day  $\text{AlCl}_3$  + Taurine 200 mg/kg/day (H & E Stain, 400 x) revealed degenerative and reduced spermatozoa and spermatids in the tubule of epididymis.



**Fig. 9 :** Epididymis of male rabbit received 20mg/kg/day  $\text{AlCl}_3$  + *Zingiber officinale* 200 mg/kg/day (H & E Stain, 400 x) revealed degenerative and reduced spermatozoa with only spermatids in the tubule of epididymis.

spermatozoa in epididymis tubule after 21 days of exposure compared to control group (Fig. 6). While, the male rabbits that treated with Taurine or *Zingiber officinale* showed reduced spermatozoa with only spermatids in epididymis tubule compared to groups treated with  $\text{AlCl}_3$  (Figs. 8 and 9), respectively. It is also observe from fig. (10) that combination of Taurine and *Zingiber officinale* give the best results with epididymal



**Fig. 10 :** Epididymis of male rabbit received 20mg/kg/day  $\text{AlCl}_3$  + combination of Taurine 100 mg/kg/day and *Zinger officinale* 100 mg/kg/day (H & E Stain, 400 x) revealed epididymal tubules filled with spermatozoa.

tubules filled with spermatozoa compared to control and other treated groups.

### Discussion

It is clear from the obtained results that  $\text{AlCl}_3$  caused a significant increase in serum levels of MDA, AST, ALT and ALP and significant ( $P < 0.05$ ) decrease in GSH, SOD, CAT, FSH, LH and Testosterone compared to the control groups. These results of the present study were agreed with those obtained by (43, 44, 45, 46), who reported that  $\text{AlCl}_3$  toxicity causes lipid peroxidation and reduced antioxidant enzymes activities. This may be due to mechanism of Al-mediated suppression of antioxidant enzymes by direct interaction of aluminum with scavenging of free radical and increase lipid peroxidation (47, 48). It has been known that aluminum accumulates in every mammal's tissues such as liver, kidneys, testis, blood, heart, bones and brain (49). Furthermore, aluminum cytotoxicity mediated through cell membranes damage in which aluminum binds to ferric iron-carrying protein transferring, as a result it decreases binding of ferrous iron. The elevation of intracellular ferrous iron led to membrane lipid peroxidation resulting membrane fluidity, changes in membrane potential, an increase in membrane permeability and changes in receptor functions (50). It is also caused alteration in structure of cellular membranes, inhibits various enzymes such as alkaline phosphatase, acetylcholinesterase, and adenylyl cyclase. Aluminum antagonizes with other elements such as calcium, magnesium, iron, silicon, phosphorus, copper, and zinc were observed in the biological systems (51). Also aluminum generates reactive oxygen species, resulting in oxidative damage of lipids, proteins and DNA molecules (52). The increase serum levels of AST and ALT may be attributed to escape of hepatic enzymes from hepatocytes damage due to cellular degeneration occurs in the liver (53). The hepatotoxicity induced by

aluminum causes accumulation of calcium ion in the mitochondria and resulted in irreversible injury to its membrane (54) leading to release of its enzymes content to the circulation (55). Furthermore, increase of ALP levels induced by exposure to Al may be attributed to either elevation of osteoblastic activity, provoked by trouble of causative to increased plasma membrane permeability or cellular necrosis of hepatic cell (56). In contrast, decreased serum levels of FSH, LH and testosterone after exposure to  $\text{AlCl}_3$  may be attributed to calcium ion is important for FSH, LH and testosterone formation and secretion, Aluminum crosses blood brain barrier obstructs voltage-sensitive calcium channels in cells that are responsible for gonadotropin releasing hormone (GnRH) formation and secretion. These diminished luteinizing hormone (LH) in the pituitary gland and then led to significantly lowered testosterone (57). Decreased serum levels of testosterone may be attributed to a direct damage of  $\text{AlCl}_3$  on Leydig cells, which are major site of testicular androgen biosynthesis through reduction of testicular luteinizing hormone (LH) receptor (58). Other studies showed that  $\text{AlCl}_3$  toxicity is associated with oxidative damage in testicular Leydig cells through reactive oxygen species (ROS) generation (59). While, (60) demonstrated that  $\text{AlCl}_3$  causes loss in ability of plasma membrane to act as a barrier, leading to loss of catalytic enzymes and substances from intracellular stores. The severe degeneration in spermatogenic stages with only Sertoli cells in testicular tissue, hypoplasia, congested blood vessels, lack of distribution of epithelial lining, degeneration of interstitial tissue, abnormal Leydig cells, degeneration and complete loss of spermatozoa in tubules of epididymis in  $\text{AlCl}_3$  treated male rabbits may be attributed to injury of sperm progression and secretory functions of epididymal cells which might be due to oxidative stress or to androgen insufficiency (61). (62) confirmed histological alterations as damages within seminiferous tubules and vascular degeneration of the germ cells and Sertoli cells cytoplasm. The impairment caused by aluminum was accompanied primarily by prolonged accumulation of aluminum in the mice testes. (63) showed that  $\text{AlCl}_3$  caused testicular toxicity as indicated by histological changes in the seminiferous tubules of the testes. That is because aluminum induced oxidative damage and the ability of aluminum to cross the blood-testis barrier after inducing oxidative stress and lipid peroxidation that damages the biological membrane of the testes and causes modification and atrophy of spermatogenic cells. (64 and 65) demonstrate that intact mitochondria with active respiration are essential for LH-induced Leydig cell steroidogenesis. Testosterone is essential for

spermatogenesis from spermatogonium to spermatide (66). (67) found that intraperitoneal injection with  $\text{AlCl}_3$  increased nitric oxide production and decreased both testicular cAMP and testosterone levels of male mice. The administration of ginger increase significantly sperm count, motility, viability, and serum total testosterone due to productive effect of ginger rhizome is reflected by the decrease MDA and increase total antioxidant capacity (68). The ethanolic extract of ginger contains a potent antioxidant components such as oil ginger polyphenol (6-gingerol), flavonoids, tannin, glycosides, saponins, and alkaloids proteins which acts as good scavengers of ROS and as powerful inhibitors of lipid peroxidation may be due to rebuilding activities of nutrient and phytochemicals found in extract (69). Ginger free phenolic and ginger hydrolysed phenolic fractions of ginger exhibited free radical scavenging, inhibit lipid peroxidation, DNA protection, indicating strong antioxidant properties (70). Furthermore, ginger reveals anti-inflammatory action by direct inhibition of cytoooxygenase -1 and cytoooxygenase -2 activity (71) also reveals larger inhibitory action toward development of pro-inflammatory signaling compound PGEs from Cox2 in LPS activated macrophages and tend to normalize the apoptotic marker caspase -3 (72). The ginger contains polyphenols which demonstrating a higher chelato-forming capacity with regard to  $\text{F}^{+3}$ , leading to prevention of hydroxyl radicals initiation which are known as inducers for lipid peroxidation (73). (74) confirmed that ginger extract reduced lipid peroxidation by retaining antioxidant enzymes activity, SOD and CAT in rats, enzymes comprise the first line defense against free radical induced damage and protection activity of enzymes by ginger may explanation major active phenolic ingredients remoted from *Zingiber officinale* (zingerone, gingerols, shogaols, gingerdiol and zingibrene) have antioxidant activity (75). The antioxidant activity of natural poly phenols is mainly because of their redox properties, which allow them to act as reducing agents, hydrogen donors, free radical scavenger, singlet oxygen quenchers and metal chelator (76). (77) have demonstrated that *Zingiber officinale* increased the activities of antioxidant enzyme may be due to ginger rhizome contains vitamins and flavonoids which their antioxidant roles have been thoroughly been proved. (78) stated that ginger contains a high level of selenium and glutathione antioxidant, thus it can be proved that these ingredients can increase level of GSH by increased supply of GSH or selenium for the activation of GPX, which can capable of reducing peroxides and hydrogen peroxide. On the other hand, other study showed that supplementation of ginger extract and sodium arsenate produces significant prophylactic

properties against sodium arsenate induced oxidative stress by means of lowering lipid peroxidation and increasing SOD, CAT and GSH content in male rats via its potent antioxidant properties and androgenic activities (79). In contrast, ameliorative effect of taurine on reproductive hormones may attributed to role of taurine to stimulate secretion of LH and FSH via its effect on hypothalamo-pituitary gonadal axis and to regulate production of testosterone from the testes by binding to membrane receptors on leydig cells and stimulates them to converted cholesterol to testosterone (80), and may also had beneficial effect on testicular biochemical pointer such as acid phosphatase (ACP), lactate dehydrogenase (LDH), sorbitol dehydrogenase (SDH), AST and ALT. On the other hand, taurine play an essential role in protective male reproduction via modulation of calcium level, osmoregulation, stability of membrane and antioxidant. Furthermore, it can act as direct antioxidant, neutralizes hydroxyl radicals and prevent lipid peroxidation and increase glutathione level as enzymatic anti-oxidant in addition to balance Na, K and Ca ATPase activity to stabilize membrane, therefore protect cell from ROS damage and oxidative stress (81), that may be significant in the spermatogenesis by improving energy and lipid metabolism to increase spermatogenic cells division and acts as antioxidant in the testis which protects the testis from oxidative stress to produced estrogen and testosterone, and from other side, may be allow to LH and FSH to regulate the increase in the levels of testosterone (82). These finding agreed with those obtained by (83) who reported that taurine believes as a potential applicant for hostility apoptosis and abnormality of testis which induced by doxorubicin and efficiently attenuated oxidative stress and apoptosis due to its potent antioxidant as well as membrane stabilizing effect. Taurine counteracts Al-induced testicular injury. Orally administration of taurine was efficient in counteracting arsenic-induced oxidative stress and attenuating testicular damage, and apoptosis of testicular tissue in Wistar rats by controlling the reciprocal regulation of Bcl-2/Bad, phospho-ERK1/2, phospho-p38, phospho-Akt, and NF-kB (84). pre-treatment with taurine could prevent cadmium-induced testicular pathophysiology in mice (85). It has been shown that Taurine stimulate testicular steroidogenesis in vivo and in vitro (86) and to encourage spermatogonial proliferation and/or meiosis (87). It is considered a capacitating agent (88), and as a sperm motility factor (89). Taurine ameliorate nuclear and mitochondrial damage may be due to antioxidant action on DNA oxidative enzymes (90), mitochondrial respiratory chain complexes (91), and keep cellular



calcium homeostasis (92) due to anti-oxidative stress, anti-inflammatory, and anti-apoptotic effects of Taurine (93,94,95,96,97).

The histopathological and morphological changes occurs in testicular and epididymal tissue after administration of AlCl<sub>3</sub> to male rabbits compared to normal control. This indicate that AlCl<sub>3</sub> induced damages in the structural and functional units of testis and epididymis, gonadotoxic, apoptosis in spermatogonia and primary spermatocytes as a result of microtubule targeting and mitotic arrest, cytotoxic effects in Leydig cells, reduced steroidogenesis results in altered spermatogenesis and spermatoc failure. These morphological changes are reliable with that confirmed by other studies such as (98, 99, 100, 101, 102, 103, 104, 105). Several studies reported that inflammation and oxidative damage are the main mechanism of AlCl<sub>3</sub> induced toxicity (106). There are several source of ROS production by tissue inflammation, lipid peroxidation, stimulation of free radicals generation and a related decrease in tissue GSH content by AlCl<sub>3</sub> lead to toxicity (107). Two recent studies (108, 109) demonstrate that intact mitochondria with active respiration are essential for LH-induced Leydig cell steroidogenesis. Accordingly, mitochondrial membrane potential, mitochondrial ATP synthesis, and mitochondrial pH are considered the key elements mediating acute steroid biosynthesis. However, tissues were improved moderately when taurine and *Zingiber officinale* were supplemented with AlCl<sub>3</sub> and return to its normal structure due to its antioxidant, anti-inflammatory and anti-apoptosis activity (Pandey and Jain, 2017).

### References

- Domingo, J. L. (1994). Reproductive and developmental toxicity of aluminum: A review. *Neurotoxicol Terato.*, **17**(4) :515-521.
- Farina, M., F. S. Lara, R. Brandao, R. Jacques and J. B. T. Rocha (2002). Effects of aluminum sulfate on erythropoiesis in rats. *Toxicol Lett.*, **132** : 131-139.
- Ganong, W. F. (2005). *Review of Medical Physiology*, 21st ed., Lange Medical Book/McGraw-Hill., 415-457.
- Bacteria, A., A. Campbell and S. Bondy (2002). Aluminum as a toxicant. *Toxicol. industrial Health*, **18** : 309-320.
- Yousef, M. I., A. M. El-Morsy and M. S. Hassan (2005). Aluminum-induced deterioration in reproductive performance and seminal plasma biochemistry of male rabbits: Protective role of ascorbic acid. *Toxicol.*, **215**: 97-107.
- Eman, E. E., Y. A. Doha and A. E. Naveen (2013). Influence of chelating therapy against aluminum chloride-induced immune suppression and hematological disorders in rabbits. *Comp Clin Pathol.*, **22**: 63 –73.
- Gonçalves, P. P. and V. S. Silva (2007) Does neurotransmission impairment accompany aluminum neurotoxicity? *J. Inorganic Biochemistry*, **101**(9): 1291-1338.
- El-Sayed, W. M., M. A. Al-Kahtani and A. M. Abdel-Moneim (2011). Prophylactic and therapeutic effects of taurine against aluminum-induced acute hepatotoxicity in mice. *J Hazard Mater.*, **192**(2) : 880-886.
- Kakimoto, M., A. Kobayashi, R. Fukuda, Y. Ono, A. Ohta and E. Yoshimura (2005). Genome-wide screening of aluminum tolerance in *Saccharomyces cerevisiae*. *Bio Metals*, **18**: 467-74.
- Yousef, M. I. (2004). Aluminum-induced changes in hemato-biochemical parameters, lipid peroxidation and enzyme activities of male rabbits: protective role of ascorbic acid. *Toxicol.*, **199**: 47-57.
- Fu, Y., F. B. Jia, J. Wang, M. Song, S. M. Liu, Y. F. Li and Q. W. Bu (2014). Effects of sub-chronic aluminum chloride exposure on rat ovaries. *Life Sci.*, **100** (1) : 61-66.
- Yuan, C. Y., Y. J. Lee and G. S. Hsu (2012). Aluminum overload increases oxidative stress in four functional brain areas of neonatal rats. *J Biomed Sci.*, **19**(1): 51.
- Sargazi, M., A. Shenkin and N. B. Roberts (2006). Aluminium-induced injury to kidneys proximal tubular cells: effects on markers of oxidative damage. *J Trace Elem Med Biol.*, **19** : 267-273.
- Shaw, C. A., Y. Li and L. Tomljenovic (2013). Administration of aluminium to neonatal mice in vaccine-relevant amounts is associated with adverse long term neurological outcomes. *J Inorg Biochem.*, **128**:237-244.
- Shirin, A. P. and P. Jamuna (2010). Chemical composition and antioxidant properties of ginger root (*Zingiber officinale*). *J Med Plant Res.*, **4**(24) : 2674-2679.
- Medoua, G. N., A. A. Egal and W. H. Oldewage-Theron (2009). Nutritional value and antioxidant capacity of lunch meals consumed by elderly people of Sharpeville, South Africa. *Food Chem.*, **115** (1): 260-264.
- Nashwa, A. A., K. A. Ahmad and S. M. Mouneir (2011). The protective effect of ginger and N- acetyl cysteine on ciprofloxacin - induced reproductive toxicity in male rats. *J Amer Sci.*, **7**(7): 741-752.
- Sakr, S. A. and G. M. Badawy (2011). Effect of ginger (*Zingiber officinale*) on metiram-inhibited spermatogenesis and induced apoptosis in albino mice. *Appl Phama Sci.*, **1**(4): 131-136.
- Rehman, R., M. Akram, N. Aktar, Q. Jabeen, K. Ahmed and H. M. Asif (2011). *Zingiber officinale* Roscoe (Pharmacological activity). *J Med Plant Res.*, **5**(3): 344-348.
- Ahumada, M. D., B. N. Timmermann and D. R. Gang (2006). Biosynthesis of curcuminoids and gingerols in turmeric (*Curcuma langa*) and ginger (*Zingiber officinale*):

- Identification of curcuminoid synthase and hydroxycinnamoyl-CoA thioesterases. *Phytochemist*, **67(18)**: 2017-2029.
21. Imm, J., G. Zhang, L. Y. Chan, V. Nitteranon and K. L. Parkin (2010). [6]-Dehydroshogaol, a minor component in ginger rhizome, exhibits quinone reductase inducing and anti-inflammatory activities that rival those of curcumin. *Food Res Int.*, **43**: 2208–2213.
  22. Choudhury, D., A. Das, A. Bhattacharya and G. Chakrabarti (2010). Aqueous extract of ginger shows anti-proliferative activity through disruption of microtubule network of cancer cells. *Food Chem Toxicol.*, **48**: 2872–2880.
  23. El Mesallamy, H. O., E. El-Demerdash, L. N. Hammad and H. M. El Magdoub (2010) Effect of taurine supplementation on hyperhomocysteinemia and markers of oxidative stress in high fructose diet induced insulin resistance. *Diabetol Metabol Syndr.*, **2**: 46-56.
  24. Caine, J. J. and T. D. Geraciotti (2016). Taurine, energy drinks, and neuroendocrine effects. *Cleve Clin J Med.* **83**: 895-904.
  25. Jong, C. J., J. Azuma and S. Schaffer (2012). Mechanism underlying the antioxidant activity of taurine: Prevention of mitochondrial oxidant production. *Amino Acids*, **42**: 2223-2232.
  26. Marcinkiewicz, J. and E. Kontny (2012). Taurine and inflammatory diseases. *Amino Acids*, **46**:7-20.
  27. Das, J. and P. C. Sil (2012). Taurine ameliorates alloxan-induced diabetic renal injury, oxidative stress-related signaling pathways and apoptosis in rats. *Amino Acids*, **43**:1509-1523.
  28. Jong, C. J., J. Azuma and S. Schaffer (2012). Mechanism underlying the antioxidant activity of taurine: Prevention of mitochondrial oxidant production. *Amino Acids*, **42**: 2223-2232.
  29. Kim, K. S., D. H. Oh, J. Y. Kim, B. G. Lee, J. S. You, K. J. Chang, H. Hyunju Chung, M. C. Yoo, H. I. Yang, J. H. Kang, Y. C. Hwang, K. J. Ahn, H. Y. Chung and I. K. Jeong (2012). Taurine ameliorates hyperglycemia and dyslipidemia by reducing insulin resistance and leptin level in Otsuka Long-Evans Tokushima fatty (OLETF) rats with long-term diabetes. *Exp Mol Med.*, **44(11)**: 665–673.
  30. Zhang, X., S. Tu, Y. Wang, B. Xu and F. Wan (2014). Mechanism of taurine-induced apoptosis in human colon cancer cells. *Acta Biochim Biophys Sin (Shanghai).*, **46(4)**:261-272.
  31. Sung, M. K., H. S. Jeon and T. Park (1994). Taurine possesses in vitro anti-mutagenic activity comparable to major antioxidant. *J Food Sci Nutri.*, **4(1)**: 43-46.
  32. Tu, S., X. L. Zhang, H. F. Wan, Y. Q. Xia, Z. Q. Liu, X. H. Yang and F. S. Wan (2018). Effect of taurine on cell proliferation and apoptosis human lung cancer A549 cells. *Oncol Lett.*, **15(4)**: 5473–5480.
  33. Cheong, S. H. and K. J. Chang (2013). Antidiabetic effect of taurine in cultured rat skeletal l6 myotubes. *Adv Exp Med Biol.*, **775**:311-320.
  34. Ramadan, B. K., M. F. Schaalan and E. S. Mahmoud (2017) Protective Effect of Taurine on Thiopurine-Induced Testicular Atrophy in Male Albino Rats. *J Steroids Horm Sci.*, **9(1)**: 192.
  35. Li, J. H., Y. Q. Ling, J. J. Fan, X. P. Zhang and S. Cui (2006). Expression of cysteine sulfinatase decarboxylase (CSD) in male reproductive organs of mice. *Histochem. Cell Bio.*, **125**: 607-613.
  36. Al-Qasoumi, S. I. (2010). Quantification of 6-gingerol in Zingiber officinale extract, ginger-containing dietary supplements tea and commercial creams by validated HPTLC densitometry.
  37. Reitman, S. and S. Franke (1956). A Colorimetric Method for the Determination of Serum Glutamic Oxalacetic and Glutamic Pyruvic Transaminases. *Ame J Clinic Patho.*, **28 (1)**: 56–63.
  38. Henry, J. B. (2001). *Clinical Diagnosis and Management by Laboratory Methods*. 18th Edition, W.B. Saunders, Philadelphia, PA.
  39. Schafer, F. and G. R. Buettner (2001). Redox environment of the cell as viewed through the redox state of the glutathione disulfide / glutathione couple. *Free Radic Biol Med.*, **30**: 1191-1212.
  40. Winderboun, C. C., R. E. Hawking, M. Brain and R. W. Carrel (1975). Determination of superoxide dismutase. *J Lab Clin Med.*, **2**: 337-341.
  41. Mueller, S., H. D. Riedel and W. Stremmel (1997). Determination of catalase activity at physiological hydrogen peroxide concentration. *Anayl Biochem.*, **245**:55-60.
  42. Mescher, A. L. and S. Junqueira (2010). *Basic histology text and atlas*. 12th edition. 2010, 1-5 .
  43. Osama, A., A. Fatma, E. Mohamed and S. Huda (2014). Studies on the protective effects of ginger extract and in combination with ascorbic acid against aluminum toxicity induced hematological disorders, oxidative stress and hepatorenal damage in rats. *Ann Vet Anim Sci.*, **15**: 136-150.
  44. Saad, H. M., M. M. Hassieb, S. S. Oda, H. G. Tohamy and A. F. Khafaga (2018). Histopathologic Study on The Toxic Effect of Aluminium Chloride on the Heart, Liver and Kidneys of Rabbits. *Alexan J Vet Sci.*, **56(1)**:102-109.
  45. Abdel-Wahab, W. M. (2012). AlCl<sub>3</sub>-Induced Toxicity and Oxidative Stress in Liver of Male Rats: Protection by Melatonin. **9(4)**:1173-1182.
  46. Onyegeme-Okerenta, B. M. and F. C. Anacletus (2016). Evaluation of aluminum toxicity and the ameliorative effect of some selected antioxidants on fecundity of matured male Wister rats (*Rattus rattus*). *Euro J Advan Resea Biol Life Sci.*, **4(2)**: 2056-5984.

47. Wen, Y. F., J. Q. Zhao, S. K. Nirala and M. Bhadauria (2012). Aluminum Induced Toxicity and Its Response to Combine Treatment of HEDTA and propolis in Rats. *Pol. J. Environ.*, **21(5)**:1437-1443.
48. Cheng, D., C. Zhu, J. Cao J and W. Jiang (2012). The protective effects of polyphenols from jujube peel (*Ziziphus Jujube* Mill) on isoproterenol-induced myocardial ischemia and aluminum-induced oxidative damage in rats. *Food and Chem Toxicol.*, **50(5)**: 1302-1308.
49. Al-Kahtani, M. A. (2010). Renal damage mediated by oxidative stress in mice treated with aluminium chloride: protective effects of taurine. *J Bio Sci.*, **10(7)**: 584-595.
50. Nehru, B. and P. Anand (2005). Oxidative damage following chronic aluminium exposure in adult and pup rat brains. *J Trace Elem Med Biol.*, **19(2-3)**: 203-208.
51. Kowalczyk, E., A. Kopffl, J. Kedzioral, J. Blaszczyk and M. Kopffl (2004). Effect of long-term aluminum chloride intoxication on selected biochemical parameters and oxidative-antioxidative balance in experimental animals. *Polish J Enviro Stud.*, **13**: 41-43.
52. El-Demerdash, F. M. (2004). Antioxidant effect of vitamin E and selenium on lipid peroxidation, enzyme activities and biochemical parameters in rats exposed to aluminium. *J Trace Elem Med Biol.*, **18(1)**:113-121.
53. Hassoun, E. A. and S. J. Stohs (1995). Comparative studies on oxidative stress as a mechanism for the fetotoxic of TCDD, endrin and lindane in C57BL/6J and DBA/2J mice. *Teratology*, **51**:186-192.
54. Mahmoud, M. E. and S. S. Elsoadaa (2013). Protective Effect of Ascorbic Acid, Biopropolis and Royal Jelly against Aluminum Toxicity in Rats. *J Nat Sci Res.*, **3(1)**: 2224-3186.
55. Türkez, H., M. I. Yousef and F. Geyikoglu. Propolis prevents aluminium-induced genetic and hepatic damages in rat liver. *Brit Indus Biol Res Asso.*, **48(10)**:2741-2746.
56. Hamaad, F. A. (2018). Protective effect of acai in combination with vitamin C against aluminum induced toxicity in rat liver. *J Bio life Sci.*, **9(1)**:2157-6078.
57. Al-Eisa, R. A. and H. A. Al-Nahari (2017). The attenuating effect of Royal Jelly on Hormonal Parameters in Aluminum Chloride (AlCl<sub>3</sub>) Intoxicated Rats. *Inter J Pharma Res Allied Sci.*, **6(2)**: 85 70-85.
58. Reza, S. M. and M. J. Palan (2006). Effect of Aluminium on Testosterone Hormones in Male Rat. *J Med Sci.*, **6(2)**: 296-299.
59. Pandey, G., G. C. Jain and H. Pareek (2014). Effects Of Aluminium Exposure On Cauda Epididymis of Wistar Rats. *CIB Tech J Pharm Sci.*, **23(4)**: 39-49.
60. Moselhy, W. A., N. A. Helmy, B. R. Abdel-Halim, T. M. Nabil and M. I. Abdel-Hamid (2012). Role of ginger against the reproductive toxicity of aluminium chloride in albino male rats. *Reprod Domest Anim.*, **47(2)**: 335-343.
61. Abdul-Rasoul, E. M., N. A. Hassan and K. H. Al-Mallah (2009). Effect of Aluminium Chloride on Sexual Efficiency in Adult Male Rats. *J Edu Sci.*, **22(4)**:27-44.
62. Mahran, A. A., A. H. A. Al-Rashidy and A. M. A. (2011). Abd El-Mawla AMA. Role of propolis in improving male rat fertility affected with aluminum chloride cytotoxicity. *Spatula DD.* **1(4)**: 189-198.
63. Khattab, F. I. K. (2008). Histological and Ultrastructural Studies on the Testis of Rat after Treatment with Aluminium Chloride. *Aust J Basic Appl Sci.*, **1(1)**:63-72.
64. Allen, J. A., T. Shankara, P. Janus, S. Buck, T. Diemer, K. H. Hales and D. B. Hales (2006). Energized, polarized, and actively respiring mitochondria are required for acute Leydig cell steroidogenesis. *Endocr.*, **147**:3924-3935.
65. Midzak, A. S., J. Liu, B. R. Zirkin and H. Chen (2006). Effects of myxothiazol on Leydig cell steroidogenesis: inhibition of luteinizing hormone-mediated testosterone synthesis but stimulation of basal steroidogenesis. *Endocr.*, **148**:2583-2590.
66. Jorsaraei, S. G., Y. R. Yousefnia, A. A. Beiky, M. R. Damavandi and A. A. Moghadmina (2008). The effect of methanolic extracts of ginger (*Zingiber officinale*) on human sperm parameters: an *in vitro* study. *Pak J Boil Sci.*, **11**: 1723-1727.
67. West, J. B. B. and S. Taylor (1997). Physiology Basis of Medical Practice 14 Ed Williams and Wilking. 1997; Pp:907-933.
68. Guo, C., C. J. Huang, M. S. Yeh and G. S. W. Hsu (2005). Aluminum induced suppression of testosterone through nitric oxide production in male mice. *Environ. Toxicol. Pharmacol.*, **19**: 33-40.
69. Mindell, E. (1992). Earl Mindell's Herb Bile. Simon and Achuster, New York; ISBN-13:9780684849065, 1992; pages:304.
70. Siddaraju, M. and S. Dharmesh (2007). Inhibition of gastric H<sup>+</sup> - K<sup>+</sup> ATP as and Helicobacter pylori growth by phenolic antioxidants of *Zingiber officinale*. *Mol Nutr Food Res.*, **51**: 324-32.
71. Penna, S. C., M. V. Medeiros, F. S. Aimbire, J. A. Sertic and M. Lopes (2003). Anti-inflammatory effect of the hydroalcoholic of *Zingiber officinal* rhizome on rat paw and skin edema. *Phytomed.*, **10**: 381-385.
72. Dugasani, S., M. R. Pichika, V. D. Nadsrajah, M. K. Balijepalli, S. Tandra and J. N. Korlakunta (2010). Comparative antioxidant and anti-inflammatory effect of [6]-gingerol, [8]-gingerol, [10]-gingerol and [6]-shogaol. *J Ethno Pharmacol.*, **127**:515-520.
73. Hassimotto, N., M. Genovese and F. Lajolo (2005). Antioxidant activity and dietary fruits, vegetables and commercial frozen fruit pulps. *J Agric Food Chem.*, **53(8)**: 2928-2935.
74. Ahmed, R. S., V. Seth and B. D. Banerjee (2000). Influence of dietary ginger on antioxidant defense system in rat: comparison with ascorbic acid. *Ind J Exp Biol.*, **38**: 604-

- 606.
75. Kota, N., P. Krishna and K. Polasa (2008). Alterations in antioxidant status of rats following intake of ginger through diet. *Food Chem.*, **106**: 991-996.
  76. Shanmugam, K. R., K. Mallikarjuna, N. Kesireddy and K. Sathyavelu Reddy (2011). Neuro-protective effect of ginger on anti-oxidant enzymes in streptozotocin-induced diabetic rats. *Food Chem Toxicol.*, **49**:893-897.
  77. Kondeti, R. S., M. Korivi, N. Kesireddy and S. R. Kesireddy (2011) Protective effect of dietary ginger on antioxidant enzymes and oxidative damage in experimental diabetic rat tissues. *Food Chem.*, **124** : 1436-1442.
  78. Jorsaraei, S. G, Y. R. Yousefina, A. A. Beiky, M. R. Damavandi and A. A. Moghadmina (2008). The effect of methanolic extracts of ginger (*Zingiber officinale*) on human sperm parameters: an *in vitro* study. *Pak J Boil Sci.*, **11**: 1723-1727.
  79. Morakinyo, A., O. Adeniyi and (2008). Arikawe A. Effect of *Zingiber officinale* on reproductive functions in the male rat. *Afr J Biomed Res.*, **11**: 329- 234.
  80. Xiao, S. P., W. L. Fu and Q. Y. (1997) Effect of taurine on development and endocrine of gonads of Yue-Huang broilers. *J South China Agr Univ.*, **18(2)**: 94-99.
  81. Yang, J. C., G.F. Wu, Y. Feng, C. M. Sum and J. M. Hu (2010). CSD mRNA expression in rats testes and the effect of taurine on testosterone secretion. *Amino Acids*, **39(1)**: 155-160.
  82. Yang, J. C., Y. Feng, C. M. Sun and J. M. Hu (2007). Effect of taurine on the secretion of reproduction hormone of male rat. *J Anhui Agri Sci.*, **35(11)** : 3283-3284.
  83. Das, U. N. (2011). *Atherosclerosis. Molecular Basis of Health and Disease*. Springer Science. 2011; Pp: 333-358.
  84. Das, J., J. Ghosh, P. Manna, M. Sinha and P. C. Sil (2009). Taurine protects rat testes against NaAsO<sub>2</sub>-induced oxidative stress and apoptosis via mitochondrial dependent and independent pathways. *Toxicol Lett.*, **187**, 201-210.
  85. Manna, P., M. Sinha and P. C. Sil (2008). Cadmium induced testicular pathophysiology: prophylactic role of taurine. *Reprod Toxicol.*, **6**: 282-291.
  86. Higuchi, M., F. T. Celino, A. Tamai, C. Miura and T. Miura (2012). The synthesis and role of taurine in the Japanese eel testis. *Amino Acids*, **43**:773-781.
  87. Meizel, S. (1985). Molecules that initiate or help stimulate the acrosome reaction by their interaction with the mammalian sperm surface. *Am J Anat.*, **174**:285-302.
  88. Meizel, S., C. W. Lui, P. K. Working and R. J. Mrsny (1980). Taurine and hypotaurine: their effects on motility, capacitation and the acrosome reaction of hamster sperm *in vitro* and their presence in sperm and reproductive tract fluids of several mammals. *Develop Growth Differ.*, **22**:483-594.
  89. Fraser, L. R. (1986). Both taurine and albumin support mouse sperm motility and fertilizing ability *in vitro* but there is no obligatory requirement for taurine. *J Reprod Fertil.*, **77** : 271-280.
  90. El-Sayed, W. M., M. A. Al-Kahtani and A. M. Abdel-Moneim (2011). Prophylactic and Therapeutic effects of taurine against aluminum induced acute hepatotoxicity in mice. *J Hazard Mater.*, **192**: 880-886.
  91. Lakshmi, Devi S. and C. V. Anuradha (2010). Mitochondrial damage, cytotoxicity and apoptosis in iron-potentiated alcoholic liver fibrosis: amelioration by taurine. *Amino Acids*, **38** : 3869-3879.
  92. Schaffer, S., J. Azuma, K. Takahashi and M. Mozaffari (2003). Why is taurine cytoprotective? *Adv Exp Med Biol.*, **526**: 307-321.
  93. Yang, J., X. Zong, G. Wu, S. Lin and Y. Feng (2015). Taurine increases testicular function in aged rats by inhibiting oxidative stress and apoptosis. *Amino Acids*, **47** : 1549-1558.
  94. Ahmed, M. A. (2015). Amelioration of nandrolone decanoate-induced testicular and sperm toxicity in rats by taurine: Effects on steroidogenesis, redox and inflammatory cascades, and intrinsic apoptotic pathway. *Toxicol Appl Pharmacol.*, **282** : 285-296.
  95. Jang, H. J. and S. J. Kim (2013). Taurine exerts anti-osteoclastogenesis activity via inhibiting ROS generation, JNK phosphorylation and COX-2 expression in RAW264.7 cells. *J Recept Signal Transduct Res.*, **33**: 387-391.
  96. Latchoumycandane, C., L. E. Nagy and T. M. McIntyre (2015). Myeloperoxidase formation of PAF receptor ligands induces PAF receptor-dependent kidney injury during ethanol consumption. *Free Radic Biol Med.*, **86**: 179-190.
  97. Zhang, Z., D. Liu, B. Yi, Z. Liao and L. Tang (2014). Taurine supplementation reduces oxidative stress and protects the liver in an iron-overload murine model. *Mol Med Rep.*, **10**: 2255-2262.
  98. Allen, J. A., T. Shankara, P. Janus, S. Buck, T. Diemer, K. H. Hales and D. B. Hales (2006). Energized, polarized, and actively respiring mitochondria are required for acute Leydig cell steroidogenesis. *Endocrinology*, **147**:3924-3935.
  99. Midzak, A. S., J. Liu, B. R. Zirkin and H. Chen (2007). Effects of myxothiazol on Leydig cell steroidogenesis: inhibition of luteinizing hormone-mediated testosterone synthesis but stimulation of basal steroidogenesis. *Endocrinology*, **148** : 2583-2590.
  100. Buraimoh, A. A., S. A. Ojo, J. O. Hambolu and S. S. Adebisi (2012). Histological study of the effects of aluminium chloride exposure on the testis of wistar rats. *Am Int J Contemporary Res.*, **2**:114-122.
  101. Pellegrini, F. and D. R. Budman (2005). Review: tubulin function, action of antitubulin drugs and new drug

- development. *Cancer Invest.*, **23**:264-273.
102. Zuse, A., H. Prinz, K. Muller, P. Schmidt, E. G. Gunther, F. Schweizer, J. H. Prehn and M. Los (2007). 9-Benzylidene-naphtho (2,3-b)thiophen-4-ones and benzylidene-9 (10H)-anthracenones as novel tubulin interacting agents with high apoptosis inducing activity. *Eur J Pharmacol.*, **575** : 34-45.
  103. Guo, C. H., C. J. Huang, S. T. Chen and G-S. W. Hsu (2001). Serum and testicular testosterone and nitric oxide products in aluminum-treated mice. *Environ Toxicol Pharmacol.*, **10** : 53-60.
  104. Dobashi, M., M. Fujisawa, T. Yamazaki, Y. Okuda, M. Kanzaki, N. Tatsumi, T. Tsuji, H. Okada and S. Kamidono (2001). Inhibition of steroidogenesis in Leydig cells by exogenous nitric oxide occurs independently of steroidogenic acute regulatory protein (star) mRNA. *Arch Androl.*, **47**:203-209.
  105. Kostia, T. S., S. A. Andria, D. Maria and R. Z. Kovaevia (2000). Inhibitory effects of stress-activated nitric oxide on antioxidant enzymes and testicular steroidogenesis. *J Steroid Biochem Mol Biol.*, **75**:299-306.
  106. Pandey, G. (2013). A review on toxic effects of Aluminum exposure on male reproductive system and probable mechanism of toxicity. *Inter J Toxicol Appli Pharma.*, **3(3)** :48-57.
  107. Ige, S. F. and R. E. Akhigbe (2012). The role of Allium cepa on aluminum-induced reproductive dysfunction in experimental male rat models. *J Hum Reprod Sci.*, **5(2)** : 200-205.
  108. Hasona, N. A. and M. Q. Ahmed (2017). Antioxidant and ameliorative effects of Zingiber officinale against aluminum Chloride Toxicity. *Intern J Chin Med.*, **1(4)**: 124-131.
  109. Kalaiselvi, A., G. A. Reddy and V. Ramalingam (2015). Ameliorating Effect of Ginger Extract (*Zingiber officinale* Roscoe) on Liver Marker Enzymes, Lipid Profile in Aluminium chloride Induced Male Rats. *Inte J Pharma Sci Drug Resea.*, **7(1)**:52-58.
  110. Pandey, G. and G. C. Jain (2017) Aluminium Chloride-Induced Testicular Effects in Rats: A Histomorphometrical Study. *Asian J Appl Sci Tech.*, **1(9)**:46-52.